

## Segmental Reconstruction of the Caudal Vena Cava Using an Autogenous Tubular Graft of the Internal Rectus Abdominus Sheath: A Pilot Study

Julius M. Liptak, Peter T. Chin, Michael S. Stephen, Edward J. Wills and Geraldine B. Hunt  
Department of Upper Gastrointestinal, Vascular Surgery and Anatomical Pathology,  
Faculty of Veterinary Science, University of Sydney, Cardiovascular Unit,  
Royal Prince Alfred Hospital, Camperdown, New South Wales 2050, Australia

**Abstract:** The aim of this study was to evaluate the mesothelial-lined internal sheath of the rectus abdominus muscle (IRAS), with and without glutaraldehyde fixation and postoperative acetylsalicylic acid administration, as an autogenous interpositional graft of the prerenal caudal vena cava in clinically normal dogs. The IRAS was harvested from the right abdominal wall, tubularized with the mesothelial surface forming the luminal surface of the graft and then placed as an interpositional segmental graft in the prerenal caudal vena cava. In three dogs, the graft was fixed in glutaraldehyde and acetylsalicylic acid was administered in the postoperative period. In the remaining three dogs, the graft was not fixed and adjunctive treatment was not administered. Ultrasound and angiography were used to evaluate patency of the caval grafts following surgery and every 7 days for a maximum of 21 days. Dogs were euthanized prior to 21 days if graft occlusion was evident on imaging studies or 21 days if the graft was patent. Endothelialization of the luminal surface of the graft was assessed by gross examination at necropsy and histologic and immunohistochemical analysis. One untreated and all three glutaraldehyde-fixed autogenous grafts remained patent for 21 days. Two untreated grafts, both non-isodiametric, thrombosed by 7 days. Histologic and immunohistochemical analyses showed mesothelial cells did not survive on the graft surface and endothelialization was only apparent in patent grafts. The IRAS is a readily available source of autogenous tissue, but untreated grafts have a low patency rate and graft fixation in glutaraldehyde and postoperative treatment with acetylsalicylic acid may be required to improve the patency rate of venous grafts in large veins such as the caudal vena cava.

**Key words:** Caudal vena cava, autogenous graft, internal rectus abdominis sheath, thrombosis

### INTRODUCTION

Diseases involving the Caudal Vena Cava (CaVC) are infrequently reported. There are three options for the surgical management of the diseased CaVC in human medicine: direct repair, ligation and reconstruction with autogenous or prosthetic graft material. The anatomic location and extent of disease will determine which option is most feasible. Furthermore, all these procedures require either temporary caval occlusion or by-pass to provide a bloodless surgical field (Baumgartner *et al.*, 1996; Huguet *et al.*, 1995; Hunt *et al.*, 1992; Langenburg *et al.*, 1994).

Ligation can only be safely performed in the prerenal CaVC (Kang *et al.*, 1997). In dogs, left renal function can be preserved following nephrectomy of the right kidney and resection of the renal CaVC with ligation of the prehepatic CaVC and left renal vein (Duckett *et al.*, 1973). An extensive potential collateral system, based on

persistence of vestigial vessels of the embryonic cardinal veins, can compensate for acute obstruction of the CaVC and left renal vein (Duckett *et al.*, 1973). Collateral circulation can also develop through the lumbar, epigastric, gonadal, ureteral and phrenicoabdominal veins (Duckett *et al.*, 1973). Ligation of the right renal vein is not possible as it lacks adequate collateral venous drainage (Duckett *et al.*, 1973).

In one human study, ligation of the CaVC was associated with 9% mortality, postoperative limb swelling in 36% and late venous complications, such as thrombosis and the development of abdominal wall varicosities, in 50% of cases (Donaldson *et al.*, 1980). Others report severe bilateral pelvic limb edema in 49-70% of cases at 1 month and 10-35% 12 months after ligation of the CaVC (Beck *et al.*, 1998). Ligation of the CaVC is tolerated better in humans with chronic diseases as an adequate collateral circulation has usually developed (Huguet *et al.*, 1995).

**Corresponding Author:** Julius M. Liptak, Department of Upper Gastrointestinal, Vascular Surgery and Anatomical Pathology, Faculty of Veterinary Science, University of Sydney, Cardiovascular Unit, Royal Prince Alfred Hospital, Camperdown, New South Wales 2050, Australia

Direct repair of the CaVC, without ligation or patch grafting, is feasible if greater than 50% of the diameter of the CaVC can be preserved (Kang *et al.*, 1997). However, the disturbance in blood flow at this site may predispose to thrombus formation and caval occlusion (Kang *et al.*, 1997).

Reconstruction of the CaVC may be required following resection of invasive tumors, traumatic laceration and management of non-malignant occlusive diseases (Baumgartner *et al.*, 1996; Beck *et al.*, 1998; Caldarelli *et al.*, 2002; Donaldson *et al.*, 1980; Duckett *et al.*, 1973; Hardwigsen *et al.*, 1979; Hunt *et al.*, 1992; Jost *et al.*, 2001; Kang *et al.*, 1997; Langenburg *et al.*, 1994; Oderich *et al.*, 2004; Sarkar *et al.*, 1998; Scherck *et al.*, 1974; Turpin *et al.*, 1977). Autogenous grafts, allografts, xenografts and prosthetic material have all been used in the venous system with disappointing patency rates (Collins *et al.*, 1960; Scherck *et al.*, 1974), except for porcine small intestinal submucosa xenografts (Jernigan *et al.*, 2004; Tucker *et al.*, 2002) and expanded polytetrafluoroethylene prosthetic grafts (Caldarelli *et al.*, 2002; Hardwigsen *et al.*, 2001; Hemming *et al.*, 2004; Jost *et al.*, 2001). The thrombogenic nature of non-autogenous graft material and unfavorable hemodynamics in the venous system, such as low-pressure and low and non-pulsatile blood flow, predispose to thrombosis and occlusion of venous grafts (Collins *et al.*, 1960; Hedeman *et al.*, 1998; Scherck *et al.*, 1974).

Autogenous vein grafts are preferred as the endothelial surface is inherently resistant to thrombosis and infection (Alavaikko, 1988). However, the use of autogenous veins for reconstruction of large veins such as the CaVC is technically challenging and time consuming (Jost *et al.*, 2001; Scherck *et al.*, 1974). Mesothelial cells are an attractive alternative to vein grafts as they are structurally and functionally similar to endothelial cells (Clark *et al.*, 1984; Hedeman *et al.*, 1998). Mesothelial cells are both fibrinolytic and anticoagulant through the production of prostaglandin I<sub>2</sub> and tissue plasminogen activator (Clark *et al.*, 1984; Hedeman *et al.*, 1998). Moreover, they are readily available in large quantities, in the form of either peritoneum or pericardium (Lam *et al.*, 2003) as autogenous grafts for the reconstruction of large veins such as the CaVC.

The purpose of this pilot study was to investigate the mesothelial-lined peritoneum, based on the internal sheath of the rectus abdominus muscle, as an autogenous graft of the prerenal CaVC to prevent the thrombotic occlusion and failure commonly associated with prosthetic and autogenous vein grafts. The prerenal CaVC is characterized by low blood pressure and low, non-

pulsatile blood flow. As a result, it is considered the gold-standard for analyzing the performance of venous grafts as graft patency improves further cranially with the increase in blood flow and pressure associated with drainage of the lumbar, renal, phrenicoabdominal and hepatic veins (Collins *et al.*, 1960; Scherck *et al.*, 1974).

## MATERIALS AND METHODS

**Animals:** Six adult, intact female Greyhounds, weighing between 21.5 and 27.0 kg, were used. This study was approved by the Animal Ethics Committee at the University of Sydney and the dogs cared for in accordance with the National Health and Medical Research Council guidelines for use of animals in research. All dogs were assessed to be clinically normal based on the results of physical examination and laboratory evaluation of PCV, total serum protein, BUN, electrolytes and venous blood gas tensions.

**Anesthesia:** Each dog was premedicated with morphine (1 mg kg<sup>-1</sup> Subcutaneously [SC]), acepromazine (0.02 mg kg<sup>-1</sup> SC) and atropine (0.04 mg kg<sup>-1</sup> SC). Core body temperature was maintained between 34 and 37.5°C with a heating mat preset to 40°C and a radiant heat lamp. General anesthesia was induced with propofol (8 mg kg<sup>-1</sup> intravenously [IV]) and maintained with a mixture of isoflurane in oxygen and nitrous oxide, at a 1:2 ratio, via a cuffed endotracheal tube in a semi-closed circle absorber system with an out-of-circuit vaporizer. A balanced electrolyte solution was administered during surgery (lactated Ringer's solution at 10 mL kg/hr IV). Antibiotic prophylaxis was provided with injectable amoxicillin-clavulanic acid (20 mg kg<sup>-1</sup> Intramuscularly [IM]) at the time of induction of general anesthesia and continued orally for 7 days postoperatively. Morphine was administered every 2 h during the procedure.

A vital signs monitor was used to measure cardiovascular parameters such as direct arterial and venous blood pressure (measured via transducers attached to a 22G cannula inserted into the dorsal pedal artery and a 12G cannula in the external jugular vein, respectively), heart rate and rhythm, indirect mean blood pressure, hemoglobin oxygen saturation and body temperature. A side-stream capnograph was used to measure end-tidal carbon dioxide and isoflurane concentrations.

**Imaging:** Contrast radiography and ultrasonography were performed pre- and postoperatively. Positive-contrast caudal vena cavograms were examined to determine the diameter of the CaVC. The dogs were placed in left lateral

recumbency and 20 mL of an iodinated contrast agent was hand-injected into the right lateral saphenous vein via an 18 G intravenous cannula. Radiographs of the caudal abdomen were exposed during injection of the last 5 mL of contrast solution. A ruler with metallic markers every 5 mm was placed between the thighs at the approximate distance of the CaVC from the x-ray cassette to enable correction for lesion-to-screen magnification and allow accurate determination of CaVC diameter.

Color-flow Doppler ultrasound was used with a linear-array 10 MHz transducer to determine the flow rate, diameter and cross-sectional area of the prerenal CaVC in 2 locations: caudal to the left renal vein and cranial to the bifurcation of the CaVC into the paired external iliac veins. The diameter and cross-sectional area measurements were compared to the aorta. The cross-sectional area was measured using elliptical and trace methods.

**Surgical technique:** Following preoperative cavography, the dogs were placed in dorsal recumbency and prepared for aseptic abdominal surgery. A ventral midline incision was performed from the xyphoid to the pubis. The prerenal segment of the CaVC was isolated and perivascular tissue was incised with electrocautery to expose the CaVC and its tributaries. The deep circumflex iliac artery and vein and the right ovarian vein were ligated with 3-0 Polydioxanone (PDS) and transected. The lumbar veins were identified along the dorsal aspect of the prerenal CaVC, ligated with 3-0 PDS and transected. The abdomen was then packed with saline-soaked laparotomy sponges while the Internal Rectus Abdominus Sheath (IRAS) was harvested.

The right abdominal wall was retracted and the IRAS was incised along its insertion on the linea alba. The IRAS was reflected medially and penetrating thoracic and lumbar veins and nerves were transected with electrocautery (Fig. 1). Due to insufficient size of the sheath alone, it was necessary to harvest the IRAS with the transversus abdominus muscle and corresponding peritoneum caudally. No attempt was made to close the donor site. The IRAS graft was then stretched with hemostats and the mesothelial surface placed on a saline-soaked gauze swab. The transversus abdominus muscle was carefully separated from the IRAS with a No. 15 scalpel blade (Fig. 2). Any defect created during this procedure was either excised, if located on the peripheral aspect of the graft, or sutured with 4-0 polypropylene on a taper needle. A segment of the IRAS was fixed in 10% buffered neutral formalin and later examined for the presence of mesothelial cells. The IRAS graft was then wrapped around a 5 mL syringe with the mesothelial surface facing inward towards the syringe. In 3 dogs,

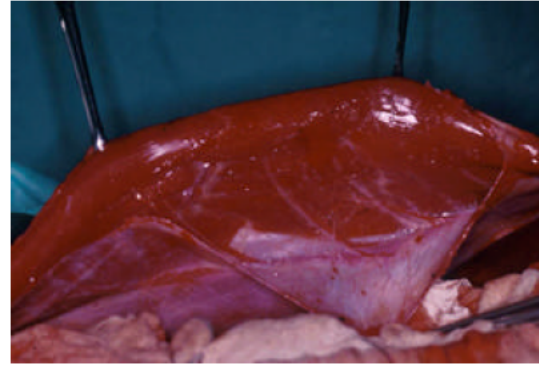


Fig. 1: The internal rectus abdominus sheath, with the transversus abdominus muscle, is being harvested from the right abdominal wall

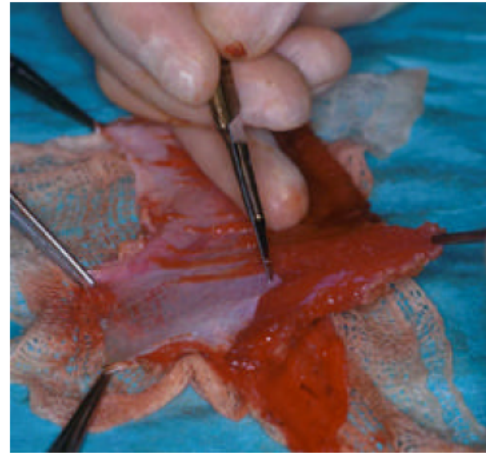


Fig. 2: The transversus abdominus muscle is removed from the deep surface of the internal rectus abdominus sheath

the graft was tubularized using a self-cutting vascular stapler and these grafts were not treated prior to interposition. In the remaining three dogs, the IRAS graft was tubularized with a double layer of 4-0 polypropylene in a continuous horizontal mattress pattern and supplemented with a layer of simple continuous 4-0 polypropylene. These grafts were then placed in a 3% glutaraldehyde solution for 10 min. The glutaraldehyde-fixed IRAS graft was then flushed with 5 L of sterile isotonic saline prior to interposition.

An unmatched transfusion of stored whole blood was administered to all dogs during and after the occlusion period. Heparin (200 IU kg<sup>-1</sup> IV) was administered approximately 30 sec prior to occlusion of the prerenal CaVC. Satinsky clamps were placed cranial to

the bifurcation of the CaVC and caudal to the left renal vein. The start of occlusion was noted and occlusion time monitored. A minimum 50 mm of CaVC was excised between the Satinsky clamps leaving a cuff of approximately 10 mm of native CaVC proximally and distally. Stay sutures of 4-0 polypropylene were placed on the cranial and caudal aspects of the caudal anastomosis. The anastomosis was performed with 4-0 polypropylene on a taper needle in a continuous pattern starting from the cranial stay suture and progressing to the caudal stay suture, or vice versa. The opposite side was sutured in the same manner. The procedure was repeated for the cranial anastomosis. The final knot was not tightened until the caudal Satinsky clamp was released to allow de-airing of the IRAS graft. The cranial Satinsky clamp was released and the total occlusion time recorded. Leaks in either the anastomoses or graft were sutured with 4-0 polypropylene in either a simple interrupted or cruciate pattern, with or without an autogenous pledget of transversus abdominus muscle. The abdominal cavity was lavaged with sterile isotonic saline. The retroperitoneal tissue was sutured loosely over the anterior aspect of the IRAS graft and CaVC with 3-0 PDS. An arteriovenous fistula caudal to the prerenal CaVC IRAS graft was not used in any dog. The linea alba was closed with 0 PDS, subcutaneous tissue with 3-0 poliglecaprone 25 and the skin with 3-0 polypropylene. A protective, non-adherent bandage was placed over the surgical wound.

**Postoperative management:** Contrast radiography and ultrasonography were repeated, as previously described, immediately after surgery. An abdominal wrap was used if blood continued to ooze from the surgical wound during the recovery period. Heparin was not reversed as the dogs were only partially heparinized and reversal may have contributed to graft thrombosis. Morphine ( $1 \text{ mg kg}^{-1} \text{ SC q 2 h}$ ) was administered for three treatments followed by buprenorphine ( $0.01 \text{ mg kg}^{-1} \text{ body weight SC q 12 h}$ ) for a further 3 treatments. Analgesia was not continued beyond this point as behaviour, activity level and cardiovascular and respiratory performance had normalized in all dogs. Intravenous fluids were changed to a maintenance solution (0.45% sodium chloride and 2.5% glucose with and additional  $20 \text{ mmol L}^{-1}$  of potassium chloride) until the dog began eating voluntarily. Acetylsalicylic acid ( $10 \text{ mg kg}^{-1} \text{ per os [PO] q 12 h}$ ) was administered during the postoperative period in dogs with glutaraldehyde-fixed IRAS grafts, but not untreated grafts. Vital signs (temperature, pulse and respiration), the surgical wound, mid-thigh diameter and subjective assessment of the size of the superficial abdominal veins were recorded twice daily.

Dogs were anesthetized 7, 14 and 21 days postoperatively and positive-contrast caudal vena cavograms and ultrasonography were performed as previously described. The diameter of the cranial, mid and caudal prerenal CaVC and the cranial and caudal anastomoses and mid-IRAS graft were measured from the cavograms. The measurements were repeated and then averaged. The diameter of the IRAS graft was expressed as a ratio of graft diameter-to-preoperative diameter of the corresponding region of the prerenal CaVC. The velocity of blood flow and the circumference and cross-sectional area of the prerenal CaVC and IRAS graft were determined in both cranial and caudal locations by ultrasonography. The measurements were repeated and then averaged. Velocity was expressed as a ratio of preoperative-to-postoperative measurements. Circumference and area of the IRAS graft were measured and also expressed as a ratio of immediate postoperative measurements-to-measurements at each time point. Dogs were euthanized with pentobarbital ( $150 \text{ mg kg}^{-1} \text{ IV}$ ) following these imaging studies at either 21 days postoperatively or earlier (i.e., 7 or 14 days after surgery) if there was radiographic or ultrasonographic evidence of IRAS *Graft occlusion*.

**Necropsy:** Necropsy was performed in all dogs. The abdominal contents and prerenal CaVC were inspected in situ. The IRAS graft was examined for gross abnormalities such as stenosis of the anastomoses and dilation of the graft. The IRAS graft was then excised with margins of normal CaVC cranially and caudally and the internal lining of the graft inspected. The graft was divided into proximal, mid and distal sections and fixed in a 10% buffered formalin solution. Tissue sections were mounted in paraffin, stained with H and E or immunohistochemical markers and examined using light microscopy at the Department of Anatomical Pathology at the Royal Prince Alfred Hospital.

Immunohistochemistry was performed to identify smooth muscle, mesothelium and endothelium in the IRAS graft. The following antibodies were used to detect mesothelium: mouse anti-mesothelial antigen (HBME-1), rabbit anti-calretinin, mouse anti-epithelial antigen (Ber-EP4) and mouse anti-cytokeratin (AE1/AE3). Rabbit anti-factor VIII-related antigen, Ulex Europaeus Agglutinin (UEA), mouse anti-a-endothelial cell (CD31) and mouse anti-a-hematopoietic progenitor cell (CD34) antibodies were used to identify endothelial cells. Smooth muscle was detected with mouse anti-a smooth muscle actin antibody. Incubation in primary antibody was followed by a peroxidase-labelled streptavidin biotin protocol. Peroxidase activity was visualized using diaminobenzidine and hydrogen peroxide (Guesdon *et al.*, 1979).

**Statistical analyses:** Imaging parameters were analyzed using a student t-test. The histologic parameters with binary outcomes were analyzed using a Fisher's Exact test. The folded-F method was used to test for homogeneity of the variances. Tests based on the pooled variance were used to test for differences between the untreated and glutaraldehyde-treated groups. A P value = 0.05 was considered significant.

## RESULTS

Untreated (dogs 1 to 3) and glutaraldehyde-fixed IRAS grafts (dogs 4 to 6) were interposed in the prerenal CaVC in three dogs each. The mean occlusion time for all dogs was 54 min (range, 45-62 min) and the mean graft length was 52 mm (range, 47-58 mm). In the untreated group, the mean occlusion time was 58.3 min (range, 54-62 min) and the mean graft length was 50.3 mm (range, 47-54 mm). In the treated group, the mean occlusion time was 49.7 min (range, 45-56 min) and the mean graft length was 53.7 mm (range, 50-58 mm). There were no significant differences in occlusion time ( $p = 0.591$ ) or graft length ( $p = 0.999$ ) between groups. The IRAS graft appeared isodiametric with the adjacent CaVC in three dogs (dogs 1, 4 and 5) (Fig. 3), dilated in two dogs (dogs 2 and 3) and reduced in one dog (dog 6). Heparinization resulted in a mild hemorrhagic discharge from the abdominal wound and subsequent wound hematoma in all dogs.

During contrast venography, there was a transient but marked decrease in systolic, diastolic and mean blood pressure following administration of the contrast agent (Nakamura *et al.*, 1994) but this did not influence anesthetic management. The mean $\pm$ SD of the ratio of the



Fig. 3: A postoperative positive-contrast cavogram showing an isodiametric internal rectus abdominus sheath graft of the prerenal caudal vena cava (dog 1)

diameter of the IRAS graft at the cranial anastomosis, mid-point and caudal anastomosis to the corresponding diameter of the prerenal CaVC preoperatively is detailed in Table 1. Two dogs in the untreated group were euthanized at 7 days postoperatively (dogs 2 and 3) because of radiographic evidence of IRAS graft occlusion and the remaining dogs were euthanized at 21 days. Collateral blood flow through the lumbar, intra-abdominal $\pm$ superficial epigastric veins was not observed in any dog on immediate postoperative positive-contrast cavograms. The degree of stenosis of the cranial and caudal anastomoses was variable. Mild stenosis of the cranial anastomosis was observed immediately following surgery in five dogs (dogs 2 to 6) and this progressed to complete occlusion in two untreated dogs (dogs 2 and 3). Mild to moderate stenosis of the caudal anastomosis was noted immediately postoperatively in three dogs (dogs 2, 3 and 6) and this progressed to either marked stenosis (dog 6) or complete occlusion (dogs 2 and 3) by the time of euthanasia in all of these dogs. Collateral blood flow was noted in four dogs (dogs 1, 2, 3 and 6) immediately prior to euthanasia.

Ultrasound examination of the prerenal CaVC was performed in all dogs. Measurements were not recorded in two dogs immediately postoperatively because both had pneumoperitoneum as a result of surgical exposure of the abdomen. The mean velocity of blood flow through the cranial and caudal prerenal CaVC prior to surgery was  $0.28 \text{ ms}^{-1}$  (range,  $0.18\text{-}0.56 \text{ ms}^{-1}$ ) and  $0.23 \text{ ms}^{-1}$  (range,  $0.12\text{-}0.32 \text{ ms}^{-1}$ ), respectively. The mean $\pm$ SD of the ratio of velocity of blood flow through the cranial and caudal anastomoses of the IRAS graft to the corresponding section of the prerenal CaVC preoperatively is detailed in Table 2. In general, the velocity of blood flow through the IRAS graft decreased immediately after surgery and, for those grafts that remained patent at euthanasia, increased from immediate postoperative velocity measurements.

The circumference and cross-sectional area of IRAS graft were measured ultrasonographically at the cranial and caudal anastomoses (Table 3 and 4, respectively). The circumference and cross-sectional area of the cranial aspect of untreated IRAS grafts increased from immediately postoperatively to the time of euthanasia, however, this increase was not significantly different from IRAS grafts fixed in glutaraldehyde. The circumference and cross-sectional area remained relatively stable in the caudal aspect of untreated IRAS grafts and all treated IRAS grafts.

Clinically, individual daily and mean postoperative thigh circumference measurements were similar to the preoperative thigh circumference regardless of whether the IRAS graft was treated or untreated and patent or occluded.

Table 1: Mean±SD diameter (cm) of the IRAS prerenal caudal vena cava graft immediately Postoperatively (P) and prior to Euthanasia (E)

|           | Cranial P | Cranial E | Mid P      | Mid E     | Caudal P  | Caudal E  |
|-----------|-----------|-----------|------------|-----------|-----------|-----------|
| Untreated | 0.62±0.09 | 0.07±0.1  | 31.27±0.71 | 0.14±0.25 | 0.69±0.36 | 0.16±0.28 |
| Treated   | 0.59±0.29 | 0.46±0.47 | 0.69±0.11  | 0.34±0.05 | 0.69±0.22 | 0.55±0.22 |
| p-value   | 0.167     | 0.136     | 0.043      | 0.067     | 0.555     | 0.771     |

Table 2: Mean±SD velocity of blood flow (ms<sup>-1</sup>) through the IRAS prerenal caudal vena cava graft immediately Postoperatively (P) and prior to Euthanasia (E)

|           | Cranial P | Cranial E | Cranial E:P | Caudal P  | Caudal E  | Caudal E:P |
|-----------|-----------|-----------|-------------|-----------|-----------|------------|
| Untreated | 0.46±0.05 | 0.18±0.31 | 0.38±0.66   | 0.67±0.12 | 0.47±0.67 | 0.64±0.85  |
| Treated   | 0.53±0.22 | 1.22±1.60 | 2.41±2.49   | 0.44±0.11 | 0.41±0.44 | 0.84±1.18  |
| p-value   | 0.082     | 0.073     | -           | 1.000     | 0.600     | -          |

Table 3: Mean±SD circumference (cm) of the IRAS prerenal caudal vena cava graft immediately Postoperatively (P) and prior to Euthanasia (E)

|           | Cranial P | Cranial E | Cranial P:E | Caudal P  | Caudal E  | Caudal P:E |
|-----------|-----------|-----------|-------------|-----------|-----------|------------|
| Untreated | 4.23±0.65 | 7.15±3.03 | 1.65±0.51   | 4.16±0.94 | 4.62±0.32 | 1.15±0.24  |
| Treated   | 3.55±0.98 | 4.37±0.71 | 1.08±0.25   | 3.49±0.74 | 3.85±0.15 | 0.93±0.00  |
| p-value   | 0.613     | 0.329     | 0.655       | 0.973     | 0.627     | -          |

Table 4: Mean±SD area (cm<sup>2</sup>) of the IRAS prerenal caudal vena cava graft immediately Postoperatively (P) and prior to Euthanasia (E)

|           | Cranial P | Cranial E | Cranial P:E | Caudal P  | Caudal E  | Caudal P:E |
|-----------|-----------|-----------|-------------|-----------|-----------|------------|
| Untreated | 1.06±0.27 | 3.96±3.29 | 3.53±2.78   | 1.10±0.59 | 1.39±0.35 | 1.44±0.63  |
| Treated   | 0.91±0.48 | 1.33±0.40 | 1.14±0.44   | 0.75±0.54 | 1.06±0.05 | 0.90±0.00  |
| p-value   | 0.468     | 0.170     | 0.222       | 1.000     | 0.201     | -          |

Necropsy was performed immediately after euthanasia in all cases. The IRAS graft was patent in four dogs (dogs 1, 4, 5 and 6). The appearances of the tissue surrounding the graft, the graft and the luminal surface of the graft were variable. Perivascular fibrous tissue encompassed the IRAS graft to varying degrees in all dogs with patent IRAS grafts. The fibrous tissue was mild and limited to only the caudal aspect of the IRAS graft in dog 1. In all dogs with treated grafts, the fibrous tissue was extensive and completely surrounded the IRAS graft. Healing of the IRAS graft donor site was apparent in all cases and omental adhesions developed in three dogs (1, 5 and 6). The graft appeared isodiametric in all dogs with no gross evidence of stenosis of either the cranial or caudal anastomoses in any dog.

The IRAS graft was occluded by an intraluminal thrombus in two dogs with untreated IRAS grafts (dogs 2 and 3) and no dogs with IRAS grafts fixed in glutaraldehyde. The IRAS graft in the dog 6 was filled with an intraluminal thrombus, however, the thrombus was canalized allowing blood flow through the graft. There was gross evidence of neointimal formation in three dogs (dogs 1, 5 and 6) (Fig. 4 and 5) with the appearance of a glistening luminal surface. However, the luminal surfaces of the remaining IRAS grafts (in dogs 2, 3 and 4) appeared dull and roughened.

The histologic findings were similar in all cases regardless of the graft preparation technique. The graft wall, at both the anastomoses and middle section, was characterized by fibrovascular proliferation which varied from being highly cellular to almost quiescent. This was accompanied by a mild to moderate mononuclear cell

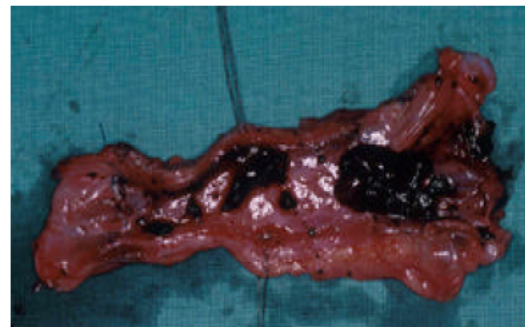

Fig. 4: The gross appearance of the patent, untreated internal rectus abdominus sheath graft with an endothelialized luminal surface and post-mortem, nonadherent thrombi (dog 1)

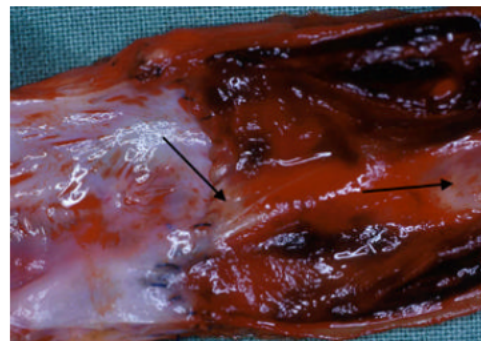


Fig. 5: Endothelialization of a glutaraldehyde-fixed internal rectus abdominus sheath graft is limited to the anastomoses and mid graft (arrows) (dog 5)

## DISCUSSION

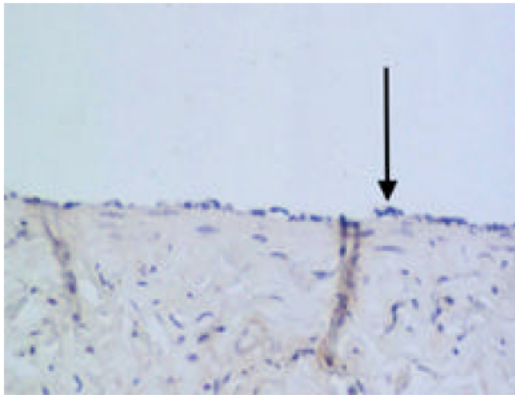


Fig. 6: Endothelial cells (arrow) on the luminal surface of the patent, untreated graft (rabbit anti-factor VIII-related antigen antibody, magnification x 660) (dog 1)

infiltrate consisting primarily of macrophages but also lymphocytes and plasma cells. The degree of collagen deposition increased while the inflammatory reaction decreased as the graft aged. Giant cells were present around suture material and remnants of skeletal muscle on the exterior surface of the graft. These skeletal muscle remnants were also associated with a mild mononuclear cell inflammatory reaction, fibroplasia and foci of calcification. Proliferation or invasion of smooth muscle from the anastomoses into the graft was not observed, although abundant smooth muscle was present in the adjacent native CaVC. Adherent thrombus was present in all grafts except that from dog 1. Recanalization of the thrombus was evident in dog 6.

Endothelial cells, which stained positive for Factor VIII but not the remaining endothelial-markers, were present but limited to the region immediately adjacent to the anastomoses in four dogs (1, 4, 5 and 6) with patent grafts. Endothelialization of the luminal surface of the graft was complete in dog 1 (Fig. 6) and progressed towards the middle sections of the graft in dog 5. This endothelial layer was fragile and lifted from the neointimal surface in two dogs (4 and 5) with treated IRAS grafts. There was no evidence of endothelial cells in any of the occluded grafts. Mesothelial cells on the harvested parietal peritoneum stained positive for AE1/AE3 but not any of the other mesothelial-markers. There was no evidence of mesothelial cells in any of the recovered grafts, which indicated loss of mesothelial cells during graft harvest or soon after insertion of the graft.

The IRAS was investigated as a potential venous graft as sufficient quantities are readily available and mesothelial cells, with similar morphology and function to endothelial cells, may reduce the incidence of graft failure due to intraluminal thrombus formation. The results of this pilot study do not support the use of an untreated IRAS graft for reconstruction of the pre renal CaVC as only one untreated IRAS graft remained patent. In comparison, all three dogs with IRAS grafts fixed in 3% glutaraldehyde and treated with acetylacetic acid postoperatively were patent at 21 days.

The patency rates of mesothelial-lined venous grafts in other studies, either in the form of a peritoneal graft or seeding the luminal surface of prosthetic grafts, have also been poor with the majority thrombosing within 7 days (Cekirdekci *et al.*, 2004; Hedeman *et al.*, 1998; Louagie *et al.*, 1996; Ribbe *et al.*, 1988; Theuer *et al.*, 1996). The failure of mesothelial cells to confer thromboresistance to venous grafts is multifactorial and includes innate properties of mesothelial cells and structural and functional loss of mesothelial cells during IRAS graft preparation.

Peritoneal grafts fail due to early thrombosis as a result of loss or dysfunction of mesothelial cells during harvest, preparation and implantation of the IRAS graft. The loss of mesothelial cells from the luminal surface of the graft results in the exposure of the submesothelial matrix which is composed of collagen, fibroblasts, fibronectin and laminin (Zerega, 1997). Collagen is highly thrombogenic and has a pivotal role in platelet adhesion, aggregation and activation (Body, 1996). Furthermore, platelet adhesion is dependent on shear rate and shear rate is primarily determined by blood flow velocity (Body, 1996). In the present study, blood flow velocity through both the cranial and caudal anastomoses was reduced by over 50% immediately postoperatively. This reduction in blood flow promotes thrombogenesis by enhancing platelet binding to components of the submesothelial matrix and minimizing the mechanical removal of fibrin and thromboplastin from the graft surface (Alavaikko, 1988; Body, 1996; Scherck *et al.*, 1974).

The two major factors which can be surgically controlled are the diameter of the graft and the diameter of the anastomoses. An isodiametric graft is preferred as blood flow is increased and turbulent blood flow minimized (Hedeman *et al.*, 1998; Plate *et al.*, 1984; Ribbe *et al.*, 1988; Scherck *et al.*, 1974). The importance of an isodiametric graft is highlighted in the present study as all four dogs with isodiametric grafts at the time of surgery (one untreated and three treated) were patent at 21 days.

In contrast, 2 dogs (2 and 3) with dilated untreated IRAS grafts were diagnosed with graft thrombosis 7 days postoperatively. Anastomotic narrowing is a recognized problem in venous grafting as veins lack the resilience of arteries and prosthetic material (Mullen *et al.*, 1996; Shore *et al.*, 1965). In the present study, stenosis was noted in both the cranial and caudal anastomoses radiographically, although stenosis of the caudal anastomosis was associated with a higher incidence of IRAS graft thrombosis and failure than stenosis of the cranial anastomosis. Patency rates of prerenal CaVC grafts have been improved by using stiffer prosthetic material and preventing anastomotic stenosis with either external or internal stents (Alavaikko, 1988; Mullen *et al.*, 1996; Shore *et al.*, 1965). An arteriovenous fistula caudal to the interpositional graft significantly improves the patency rate of venous grafts in the CaVC (Cekirdekci *et al.*, 2004), however, an arteriovenous fistula was not used in the present study as our aim was to investigate mesothelial-lined peritoneum as an autogenous graft material and the effects of glutaraldehyde-fixation on graft patency.

Glutaraldehyde was used to fix IRAS grafts to improve the handling characteristics and patency rates of the IRAS graft. All three glutaraldehyde-fixed IRAS grafts remained patent compared to only one of the untreated grafts. Glutaraldehyde-fixation results in stabilization of matrix proteins by intra- and intermolecular cross-linking of collagen molecules, destruction of mesothelial cells and fibroblasts and preservation of the viscoelastic properties of the native material (Itoh *et al.*, 1989; Jayakrishnan and Jameela, 1996). Glutaraldehyde fixation increases bending stiffness which may improve anastomotic technique and minimize graft compression by positive intra-abdominal pressure and abdominal viscera (Jayakrishnan and Jameela, 1996; Theuer *et al.*, 1996). Glutaraldehyde-fixation has been shown experimentally to confer thromboresistance to graft surfaces, but the mechanisms are unknown (Alavaikko, 1988). Dialdehyde, which is a component of commercial glutaraldehyde, increases the electronegativity of the graft surface which minimizes thrombus development (Alavaikko, 1988; Jayakrishnan and Jameela, 1996). Furthermore, the elimination of mesothelial cells and fibroblasts may be beneficial if they express prothrombotic tendencies following grafting (Hedeman *et al.*, 1998).

At necropsy, glutaraldehyde-fixed IRAS grafts differed from untreated grafts in that they were associated with a marked perigraft fibrous reaction. This reaction may increase graft rigidity and improve patency as sequential ultrasonographic measurements showed that the circumference and cross-sectional area of treated IRAS grafts remained relatively stable from surgery to

ethanasia while the circumference and area of untreated grafts tended to increase. These ultrasonographic findings contradict the conclusions of some studies which suggest that the fibrotic reaction may be progressive and ultimately result in graft failure (Plate *et al.*, 1984; Shore *et al.*, 1965).

Endothelialization of the luminal surface of the graft is the ultimate goal in vascular grafting as it prevents intraluminal thrombosis and graft failure. Complete endothelialization of venous grafts is rare, however, especially if the graft length exceeds 30 mm, as endothelial cells migrate from the anastomoses over the luminal surface of the graft but the life span of endothelial cells is limited to approximately 70 divisions (Shore *et al.*, 1974). Hence, endothelialization of longer grafts is restricted by endothelial cell aging. In one human study, only 53% of 80 mm grafts remained patent compared to 80% of 30 mm grafts (Shore *et al.*, 1974). The mean length of the IRAS graft in the present study was 52 mm.

Endothelial cells were identified in all four IRAS grafts which remained patent for 21 days. However, only the patent, untreated IRAS graft was completely endothelialized while endothelialization was limited to the anastomoses in the treated IRAS grafts. Furthermore, the endothelial cells in treated IRAS grafts were poorly anchored to the underlying neointima. This endothelial fragility has previously been reported in glutaraldehyde-tanned collagen grafts in the porcine prerenal CaVC and is a potential source of embolization and thrombosis formation (Alavaikko, 1988; Ratto *et al.*, 1991). Conversely, with more time, the neointima and endothelial layer may have been stabilized by invading fibrous connective tissue (Martakos and Karwoski, 1995).

Pelvic limb edema is a common sign of occlusion of prerenal CaVC grafts in humans (Beck *et al.*, 1998; Mullen *et al.*, 1996). The mean postoperative thigh circumference was not greatly different to the preoperative thigh circumference in dogs with patent and occluded IRAS grafts. The lack of peripheral edema is due to the rapid development of an extensive collateral system in dogs and supports clinical observations that acute occlusion of the prerenal CaVC is well tolerated in dogs (Duckett *et al.*, 1973).

Prophylactic treatment with anticoagulant and antiplatelet agents is effective in reducing the incidence of thrombotic occlusion of venous grafts Berqqvist, 1998. In the present study, all dogs were partially heparinized prior to clamping of the CaVC and the IRAS graft was stored in a solution of heparinized isotonic saline. The half-life of IV unfractionated heparin, which was used in the present study, is approximately 40 min in dogs (Jacobes *et al.*, 1999). Thrombosis of 2 untreated IRAS



grafts is unlikely to be caused by the occlusion time of the prerenal CaVC exceeding the half-life of unfractionated heparin because there were no differences in occlusion times between dogs and the efficacy of heparin therapy was demonstrated by the presence of undesirable side-effects, such as persistent hemorrhage from the abdominal wound and wound hematomas, which were observed in all dogs. Warfarin is an alternative to heparin, but studies have shown an increased incidence of morbidity and mortality and no improvement in the patency rate of venous grafts (Jacobes *et al.*, 1999).

Antiplatelet therapy is essential in the prevention of intraluminal thrombosis as thrombus formation in venous grafts is dependent on the aggregation and activation of platelets (Plate *et al.*, 1984; Scherck *et al.*, 1974). Antiplatelet therapy was not used in dogs with untreated IRAS grafts because we aimed wanted to investigate the performance of untreated grafts without ancillary treatment. The performance of untreated grafts may have been improved with the administration of acetylsalicylic acid during the peri- and postoperative periods. Medical dissolution or surgical removal of the thrombus was not attempted in the present study, but thrombolytic agents, such as streptokinase, have been used successfully in dogs with venous and arterial thrombosis (Ramsey *et al.*, 1996).

There are a number of limitations which must be considered when interpreting the results of this study. This study was designed as a pilot study to investigate whether untreated IRAS grafts would remain patent in the prerenal CaVC of dogs. The intention of a pilot study is to investigate a new procedure or treatment prior to large scale studies. As such, a pilot study permits researchers to determine whether the procedure or treatment warrants further and more detailed investigation, but does not allow firm conclusions to be made based on such limited data. In the present study, we were able to determine that untreated IRAS grafts did not appear suitable for autogenous reconstruction of the prerenal CaVC. However, these results may have been negatively affected by surgical technique and the number of different variables between the two groups. Only non-isodiametric grafts thrombosed and hence it is possible that the patency rates of treated and untreated IRAS grafts may not have been greatly different if the two remaining untreated IRAS grafts were also isodiametric. This has added importance as only the isodiametric untreated IRAS graft was completely endothelialized. We also included one treated IRAS graft as patent based on the results of consecutive imaging studies, but there was evidence of occlusion and subsequent recanalization of this graft at necropsy. The results for the treated IRAS grafts may not

have appeared as encouraging if this graft was defined as thrombosed. Lastly, there were a number of differences between the two groups which may account for the disparity in patency rates, including graft tubularization technique (stapler versus sutures), glutaraldehyde fixation and postoperative treatment with acetylsalicylic acid. Preferably, the study should have been designed to test the effects of a single variable, such as untreated versus treated IRAS grafts. However, the primary aim of the study was to evaluate whether mesothelial-lined untreated IRAS grafts could successfully be used for segmental reconstruction of the prerenal CaVC and we believed that comparison to clinically-proven treatments (e.g., glutaraldehyde fixation and postoperative acetylsalicylic acid) aimed at maximizing patency rates was valid.

## CONCLUSION

In conclusion, the IRAS is readily available and easily harvested from the abdominal cavity. Tubularization of the IRAS is relatively simple in comparison to historic reports of other techniques utilizing autogenous material. Based on the results of this pilot study, glutaraldehyde fixation of the IRAS graft and postoperative treatment with acetylsalicylic acid improved the performance and patency rate of IRAS grafts in the prerenal CaVC in dogs and warrants further investigation as an autogenous venous graft.

## ACKNOWLEDGEMENT

The authors would like to thank Drs. Chris Tan, Saana Zaki, Merran Govendir, Robert Nicoll, Richard Malik and Paul Canfield for their assistance with case management and interpretation of results and Ms. Gabrielle Monteith for statistical analyses.

## REFERENCES

- Alavaikko, A., 1988. Spiral autogenous venous graft in the replacement of large vessels. An experimental study with special reference to replacement of the caudal vena cava, *Acta Chir. Scand. Suppl.*, 542: 1-42.
- Baungartner, F., R. Scott, R. Zane, J. Gelman, J. Rajfer, B. Ages, H. Vargas, S. Klein and J. Milliken, 1996. Modified venovenous bypass technique for resection of renal and adrenal carcinomas with involvement of the caudal vena cava, *Eur. J. Surg.* 162: 59-62.
- Beck, S.D.W., S.G. Lalka and J.P. Donohue, 1998. Long-term results after caudal vena caval resection during retroperitoneal lymphadenectomy for metastatic germ cell cancer. *J. Vasc. Surg.*, 28: 808-814.

- Bergqvist, D., 1998. Modern aspects of prophylaxis and therapy for venous thromboembolic disease, *Aust. N.Z. J. Surg.*, 68: 463-468.
- Body, S.C., 1996. Platelet activation and interactions with the microvasculature. *J. Cardiovasc. Pharmacol.* 27 Suppl., 1: S13-S25.
- Caldarelli, G., A. Minervini, M. Guerra, G. Bonari, C. Caldarelli, Minervini R., Prosthetic replacement of the caudal vena cava and the iliofemoral vein for urologically related malignancies, *B.J.U. Int.*, 90: 368-374.
- Cekirdekci, A., M.K. Bayar, S. Yilmaz, M. Cihangiroglu, E. Ayan, M. Duran, T. Bakalim, D. Kaya and O. Gokce, 2004. Reconstruction of the vena cava with peritoneum: The effect of temporary distal arteriovenous fistula on patency (an experimental study), *Eur. J. Vasc. Endovasc. Surg.*, 27: 84-88.
- Clark, J.M.F., R.M. Pittilo, I.J. Nicholson, N. Woolf, and A. Marston, 1984. Seeding Dacron arterial prostheses with peritoneal mesothelial cells: A preliminary morphological study. *Br. J. Surg.*, 71: 492-494.
- Collins, H.A., G. Burrus and M.E. De Bakey, 1960. Experimental evaluation of grafts in the canine caudal vena cava. *Am. J. Surg.*, 99: 40-44.
- Di Zerega, G.S., 1977. Biochemical events in peritoneal tissue repair. *Eur. J. Surg.*, 577: 10-16.
- Donaldson, M.C., L.S. Wirthlin and G.A. Donaldson, 1980. Thirty-year experience with surgical interruption of the caudal vena cava for prevention of pulmonary embolism. *Ann. Surg.*, 191: 367-372.
- Duckett, J.W., J.H. Lifland and P.C. Peters, 1973. Resection of the caudal vena cava for adjacent malignant diseases. *Surg. Gyn. Obst.* 136: 711-716.
- Guesdon, J.L., T. Ternyck and S. Avrameas, 2001. The use of avidin-biotin interaction in immunoenzymatic techniques. *J. Histochem. Cytochem.* 27: 1131-1139.
- Hardwigsen, J., P. Baqué, B. Crespy, V. Moutardier, J.R. Delpero and Y.P. Le Treut, 2001. Resection of the caudal vena cava for neoplasms with or without prosthetic replacement: A 14-patient series, *Ann. Surg.*, 233: 242-249.
- Hemming, A.W., A.I. Reed, M.R. Langham, S. Fujita, and R.J. Howard, 2004. Combined resection of the liver and caudal vena cava for hepatic malignancy. *Ann. Surg.*, 239: 712-721.
- Huguet, C., M. Ferri and A. Gavelli, 1995. Resection of the suprarenal caudal vena cava. The role of prosthetic replacement. *Arch. Surg.*, 130: 793-797.
- Hunt, G.B., R. Malik, C.R. Bellenger and M.R. Pearson, 1992. A new technique for surgery of the caudal vena cava in dogs using partial venous inflow occlusion. *Res. Vet. Sci.*, 52: 378-381.
- Itoh, T., J. Kamayashi, T. Tsujinaka, M. Sakon, T. Ohshiro and T. Mori, 1989. Pathogenesis of early thrombus formation in experimental vein graft. *Thromb. Res.*, 53: 257-265.
- Jacobs, C., S. Grebe, M. Kietzmann and R. Mischke, 1999. Pharmacokinetics of an unfractionated heparin (Liquemin) in the dog after intravenous and subcutaneous application based on heparin activity. *Deut. Tierarzt. Wochen.*, 106: 478-481.
- Jayakrishnan, A. and S.R. Jameela, 1996. Glutaraldehyde as a fixative in bioprostheses and drug delivery matrices. *Biomate.*, 17: 471-484.
- Jernigan, T.W., M.A. Croce, C. Cagiannos, D.H. Shell C.R. Handorf and T.C. Fabian, 2004. Small intestinal submucosa for vascular reconstruction in the presence of gastrointestinal contamination. *Ann. Surg.*, 239: 733-740.
- Hedeman, J.P.P., H.J.M. Verhagen, G.J. Heijnen-Snyder, T.J. Van Vroonhoven, J.J. Sixma, P.G. De Groot, and B.C. Eikelboom, 1998. Thrombogenesis of different cell types seeded on vascular grafts and studied under blood-flow conditions. *J. Vasc. Surg.*, 28: 1094-1103.
- Jost, C.J., P. Gloviczki, K.J. Cherry, M.A. McKusick, W.S. Harmsen, G.D. Jenkins and T.C. Bower, 2001. Surgical reconstruction of iliofemoral veins and the caudal vena cava for non-malignant occlusive disease. *J. Vasc. Surg.*, 33: 320-328.
- Kang, J.S., J.H. Kim, S.K. Park, S.S. Sohn, J.M. Kim and K.K. Park, 1997. Enteral patch repair of the vena caval defect: an experimental study. *Int. Surg.*, 82: 72-75.
- Lam, B.K., G.B. Pettersson and D.P. Vogt, 2003. Urgent caudal vena cava replacement with an autologous pericardium tube graft. *J. Thorac. Cardiovasc. Surg.*, 126: 2101-2103.
- Langenburg, S.E., L.H. Blackbourne, J.W. Sperling, S.A. Buchanan, S.N. Sinclair and I.L. Kron, 1994. Management of renal tumors involving the caudal vena cava. *J. Vasc. Surg.*, 20: 385-388.
- Louagie, Y., A. Legrand-Monsieur, C. Remacle, P. Maldague, L. Lambotte and R. Ponlot, 1986. Morphology and fibrinolytic activity of canine autogenous mesothelium used as a venous substitute. *Res. Exp. Med.*, 186: 239-247.
- Martakos, P. and T. Karwoski, 1995. Healing characteristics of hybrid and conventional polytetrafluoroethylene vascular grafts, *A.S.A.I.O. J.* 41: M735-M741.
- Mullen, J.C., G. Lemermeyer, J. Tittley, F.M. Ameli, A.G. Lossing and M.A. Jewett, 1996. Metastatic testicular tumor requiring caudal vena cava resection, *Urology*, 47: 263-265.

- Nakamura, H., M. Kurata, K. Haruta and K. Takeda, 1994. Effects of ionic and non-ionic contrast media on cardiohemodynamics and quality of radiographic image during canine angiography. *J. Vet. Med. Sci.*, 56: 91-96.
- Oderich, G.S., J.M. Panneton, J. Hofer, T.C. Bower, K.J. Cherry *et al.*, 2004. Iatrogenic operative injuries of abdominal and pelvic veins: A potentially lethal complication. *J. Vasc. Surg.*, 39: 931-936.
- Plate, G., L.H. Hollier, P. Golviczki, M.K. Dewanjee and M.P. Kaye, 1984. Overcoming failure of venous vascular prostheses *Surgery*, 96: 503-510.
- Ramsey, C.C., D.P. Burney D.K. Macintire and S. Finn-Bodner, 1996. Use of streptokinase in 4 dogs with thrombosis. *J. Am. Vet. Med. Assoc.*, 209: 780-785.
- Ratto, G.B., P. Romano, M. Truini, M. Frascio., S. Rovida, A. Badini and D. Zaccheo, 1991. Glutaraldehyde-tanned mandril-grown grafts as venous substitutes. *J. Thorac. Cardiovasc. Surg.*, 102: 440-447.
- Ribbe, E.B., E.B.B.A. Jönsson, L.E.H. Norgren, S.E. Strand and J.L. Thorne, 1988. Platelet aggregation on peritoneal tube grafts and double velour grafts in the caudal vena cava of the pig. *Br. J. Surg.*, 75: 81-85.
- Sarkar, R., F.R. Eilber, H.A. Gelabert and W.J. Quinones-Baldrich, 1998. Prosthetic replacement of the caudal vena cava for malignancy. *J. Vasc. Surg.*, 28: 75-83.
- Scherck, J.P., M.D. Kerstein and H.C. Stansel, 1974. The current status of vena caval replacement. *Surgery*, 76: 209-233.
- Shore, J.M., S.M. Greenstone, T.B. Massell, E.C. Heringman and K. Wagner, 1965. A comparative study of canine venous autografts (the influence of graft diameter and external anastomotic support). *J. Cardiovasc. Surg.*, 6: 67-75.
- Theuer, C.J., T.M. Bergamini, H.H. Theuer, C.D. Burns, M.L. Proctor and R.N. Garrison, 1996. Vena cava replacement with a peritoneum-lined vascular graft. *A.S.A.I.O. J.*, 42: 266-270.
- Tucker, O.P., T. Syburra, M. Augstburger, G. Van Melle, S. Gebhard, F. Bosman and L.K. Von Segesser, 2002. Small intestine without mucosa as a growing vascular conduit: A porcine experimental study. *J. Thorac. Cardiovasc. Surg.*, 124: 1165-1175.
- Turpin, I., S. State and A. Schwartz, 1977. Injuries to the caudal vena cava and their management. *Am. J. Surg.*, 134: 25-30.