Received: 24 November 2018 | Revised: 11 April 2019 | Accepted: 1 May 2019

DOI: 10.1111/vsu.13239

ORIGINAL ARTICLE – CLINICAL

WILEY

Perioperative complications and outcome after surgery for treatment of gastric carcinoma in dogs: A Veterinary Society of Surgical Oncology retrospective study of 40 cases (2004–2018)

Brittany Abrams DVM[1] | Vincent A. Wavreille DVM, MS, MRCVS, DACVS[1] | Brian D. Husbands DVM, DACVIM (Oncology)[2] | Brad M. Matz DVM, MS, DACVS[3] | Federico Massari DVM, DECVS[4] | Julius M. Liptak BVSc, MVetClinStud, FACVSc, DACVS, DECVS[5] | Megan T. Cray VMD[6] | Carlos Henrique de Mello Souza DVM, MS, DACVIM (Oncology), DACVS[7] | Brandan G. Wustefeld-Janssens BVSc, DECVS[8] | Michelle L. Oblak DVM, DVSc, DACVS[9] | Lillian Su DVM, MVSc, CCRP, DACVS[10] | Laura E. Selmic BVetMed (Hons), MPH, DACVS, DECVS, MRCVS[1]

[1]Department of Veterinary Clinical Sciences, College of Veterinary Medicine, The Ohio State University, Columbus, Ohio

[2]Department of Veterinary Clinical Sciences, College of Veterinary Medicine, University of Minnesota, St Paul, Minnesota

[3]Department of Clinical Sciences, College of Veterinary Medicine, Auburn University, Auburn, Alabama

[4]Department of Surgery, Clinica Veterinaria Nervianese, Milan, Italy

[5]Department of Surgery, VCA Canada-Alta Vista Animal Hospital, Ottawa, Ontario, Canada

[6]Department of Surgery, Angell Animal Medical Center, Boston, Massachusetts

[7]Department of Small Animal Clinical Sciences, College of Veterinary Medicine, University of Florida, Gainesville, Florida

[8]Department of Veterinary Small Animal Clinical Sciences, College of Veterinary Medicine and Biomedical Sciences, Texas A&M University, College Station, Texas

[9]Department of Clinical Studies, Ontario Veterinary College, University of Guelph, Guelph, Ontario, Canada

[10]Sunstone Veterinary Specialists, Portland, Oregon

Abstract

Objective: To describe the clinical characteristics, perioperative complications, and outcomes in dogs surgically treated for gastric carcinoma.

Study design: Multi-institutional retrospective case series.

Animals: Forty client-owned dogs with histologically confirmed gastric carcinoma.

Methods: Medical records were reviewed for preoperative diagnostics, surgery, histopathology, postoperative complications, adjuvant chemotherapy, disease progression, and survival. Variables were assessed for associations with outcome by using Cox proportional hazards regression analysis.

Results: Surgical treatment included partial gastrectomy (28 dogs), Billroth I (9 dogs), subtotal gastrectomy (2 dogs), and submucosal resection (1 dog). Major postoperative complications occurred in 8 of 40 dogs, including septic peritonitis secondary to dehiscence in 4 dogs. The median progression free interval was 54 days, and the median survival time (MST) was 178 days (range, 1–1902). According to multivariable analysis results, experiencing an intraoperative complication was associated with an increased risk of death (hazard ratio [HR] 3.5, 95% CI 1.1–9.8, $P = .005$), and administration of adjuvant chemotherapy correlated with an improved survival (HR 0.4, 95% CI 0.2–0.9, $P = .03$).

Conclusion: In this population of dogs, MST exceeded historically reported data, major postoperative complication rates were comparable to established literature, and administration of adjuvant chemotherapy was associated with improved survival.

 © 2019 The American College of Veterinary Surgeons

Correspondence
Vincent A. Wavreille, Department of Veterinary Clinical Sciences, 601 Vernon Tharp Street, Columbus, OH, 43210.
Email: vwavreille@gmail.com

Clinical significance: Results from this study may be used to counsel owners more accurately regarding prognosis for dogs undergoing surgical excision for gastric carcinoma.

1 | INTRODUCTION

Gastric neoplasia is a rare clinical entity, representing less than 1% of canine neoplasms.[1-3] In dogs, adenocarcinoma is the most common type of gastric malignancy, accounting for 70%–80% of cases.[1,4] A report of a recent study in which the Norwegian canine cancer registry was used described a prevalence of 0.16% for canine gastric carcinoma.[5]

The treatment of choice for localized gastric adenocarcinoma is complete surgical resection.[4] However, because of the vague, nonspecific clinical signs, such as chronic intermittent vomiting, progressive weight loss, and poor appetite, these diagnoses often are not identified until the disease is advanced. Whether surgical treatment is futile in cases with extensive gastric involvement and metastatic spread is currently unknown.

Reported survival times in untreated dogs are less than 3 months after the onset of clinical signs.[1,4,6] Limited information is available in the veterinary literature regarding clinical outcome after surgical resection of gastric carcinoma. Studies evaluating dogs that have had surgery to treat gastric carcinoma have been restricted to case reports and case series that included multiple gastric tumor types.[1,4,7-15] To the best of the authors' knowledge, there have only been 45 cases in dogs reported across 23 publications.[1,4,7,10-29] The overall median survival time (MST) after surgery in these cases was 72 days.[1,4,7,10-29] Contemporary information to help guide treatment recommendations is critically needed.

The objective of this study was to describe the clinical characteristics, perioperative complications, and outcome in a large cohort of dogs with gastric carcinoma treated with surgery and evaluate factors influencing survival. We hypothesized that the incidence of major postoperative complications would be low and that adjuvant chemotherapy would not have a benefit on survival time.

2 | MATERIALS AND METHODS

2.1 | Study cases

A multicenter investigation was planned with solicitation of cases from private practices and academic veterinary centers across the world. Cases were collected via the Veterinary Society of Surgical Oncology (VSSO) listserv after study design approval by the VSSO research committee. Inclusion criteria for cases included dogs with a histologically confirmed diagnosis of gastric carcinoma that were treated with surgical excision between January 1, 2004 and May 1, 2018. Cases were excluded when dogs survived to discharge but subsequent follow-up information could not be obtained by telephone contact with the owners or primary care veterinarians after hospital discharge.

2.2 | Procedures

Medical records of cases that fit inclusion criteria were reviewed. Data collected from medical records included signalment, body weight, clinical signs at presentation, duration of clinical signs prior to presentation, and preoperative diagnostic tests and findings (including complete blood count, serum biochemistry panel, cytology, histopathology from endoscopic biopsy, thoracic radiographs, abdominal ultrasound [AUS], computed tomography [CT], and endoscopy). In addition, information about tumor size and location, description of surgery, presence or development of metastasis, perioperative complications, histologic diagnosis, adjuvant therapy (if any), and date and cause of death. The term *partial gastrectomy* was used to describe any procedure that removed ≤70% of the stomach. The term *subtotal gastrectomy* was used to describe >70% but not complete removal of the stomach. Adverse events secondary to chemotherapy were graded according to the Veterinary Cooperative Group Common Terminology Criteria for Adverse Events v1.1.[30] The intended surgical excision was categorized as either wide or marginal, according to the Enneking classification,[31] and the surgical margin width was recorded when available. Complications occurring in either the intraoperative or the postoperative period were classified as major or minor. Minor complications were defined as events that were self-limiting or that resolved with medical management.[32] Major complications were defined as events requiring a surgical revision, resulting in death, or leading to euthanasia.[32]

2.3 | Measures of outcome

The progression-free interval (PFI) was calculated as the number of days from the date of surgery to the date of first detection of local recurrence or metastasis. Follow-up diagnostics were not standardized and either were performed routinely at variable intervals according to individual institution surveillance protocols or were prompted by clinical signs. Dogs were censored in the PFI analysis when development of local recurrence or metastasis was not documented by the time of last follow-up or the time of death.

The overall survival time was calculated as the number of days from the date of surgery to death. For survival time calculations, the end point was defined as death or euthanasia resulting from any cause. Dogs that were alive at last follow-up or were lost to follow-up were censored in the survival analysis.

2.4 | Statistical analysis

Continuous variables were tested for normality by using graphical methods, a Shapiro–Wilk test, skewness, and kurtosis. When data were normally distributed, they were summarized by using the mean and standard deviation (SD). The median and range were used to summarize skewed data. Categorical data were described with frequencies and percentages.

Kaplan–Meier methods were used to generate survival curves and calculate the median PFI and MST with 95% CI. Cox proportional hazards regression analysis was used to evaluate for associations between baseline and treatment variables and survival. Variables assessed included age, weight, duration of clinical signs, tumor location, tumor size, presence of metastases at diagnosis, surgical intent, occurrence of intraoperative or postoperative complications, completeness of surgical margins (complete vs incomplete), and whether chemotherapy was administered. When survival analysis was performed, major and minor complications were pooled together, and dogs were considered to have received adjuvant chemotherapy if they received at least 1 dose of a chemotherapeutic agent. Multivariable Cox proportional hazards regression analysis was performed to assess variables for associations with overall survival. The proportional hazards assumption for the model was checked by evaluating the graph of the log(−log[survival]) vs log of survival time graph and Schoenfeld residuals. Variables were entered into the model if univariable analyses showed Wald $P < .2$. Backward elimination was used for model selection; variables were removed if likelihood ratio test and/or Wald $P > .05$. Backward elimination was used to reduce the inflation of type I error and to improve the control of negative confounding factors. Hazard ratios (HR) were calculated with 95% Wald CI for each variable.

Statistical analyses were performed in SAS (version 9.4 for Windows; SAS Institute, Cary, North Carolina). Statistical significance was set at $P < .05$.

3 | RESULTS

3.1 | Demographics

Forty dogs from 13 institutions met the inclusion criteria. Breeds represented included golden retriever (3), Labrador retriever (3), chow (2), greyhound (2), beagle (2), shih tzu (2), Scottish terrier (2), dachshund (2), and 1 each of German wirehaired pointer, Belgian Tervuren, Bouvier des Flandres, miniature pinscher, cane corso, Siberian husky, field spaniel, toy poodle, standard poodle, pug, border collie, and collie; there were 10 mixed-breed dogs. There were 23 spayed females, 14 castrated males, and 3 intact males. Mean age at the time of surgery was 9.7 years (SD ± 2.0), and mean weight was 21.2 kg (SD ± 12.2).

3.2 | Clinical findings

The median duration of clinical signs prior to presentation was 90 days (range, 2–365). Clinical signs included vomiting (7/40; 92.5%), hyporexia (19/40; 47.5%), weight loss (18/40; 45.0%), lethargy (4/40; 10.0%), hematemesis (3/40; 7.5%), melena (3/40; 7.5%), and ptyalism (3/40; 7.5%). One dog exhibited a ravenous appetite despite concurrent weight loss.

Preoperative hematology and serum biochemistry results were available for 32 and 37 cases, respectively. Hematologic abnormalities, documented in 12 of 32 dogs, and serum biochemical abnormalities, documented in 12 of 37 dogs, were nonspecific and animal dependent. Thoracic imaging was performed prior to surgery in all but 1 case with radiography (32/39) or CT (7/39). Evidence of pulmonary metastasis was not observed in any case. Abdominal imaging was performed in 37 dogs (AUS [29], [CT, 7], AUS and CT [1]), and 1 dog had an exploratory celiotomy performed prior to referral. According to abdominal imaging results, locoregional lymph node enlargement was identified in 10 dogs, and a mesenteric nodule was observed in 1 dog. Ultrasound-guided fine-needle aspiration of the gastric mass was performed in 12 dogs. In 8 dogs, results were either inconclusive or nondiagnostic because of low cellularity. In the 4 cases with cytologic abnormalities, results were consistent with suppurative, nonseptic inflammation (1) or epithelial neoplasia (3). Endoscopic biopsies were performed in 24 dogs and concurred with the final histopathology in 16 cases. For the remaining 8 cases in which results were discordant, the interpreted endoscopic biopsies were consistent with inflammation (5), leiomyoma (1), hyperplasia (1), and mucosal hyperplasia and dysplasia with precancerous changes (1).

3.3 | Surgical findings

Surgical procedures included partial gastrectomy (28/40), Billroth I (9/40), subtotal gastrectomy (2/40), and submucosal resection via a gastrotomy (1/40). Two dogs that had Billroth I required a cholecystoduodenostomy. Lymph node excision, lymph node biopsy, and liver biopsy were performed in 15, 2, and 6 dogs, respectively.

Tumors were reported to arise from the following locations in the stomach: lesser curvature (9/40), greater curvature (3/40),

pylorus (7/40), antrum (6/40), fundus (2/40), cardia (1/40), and body (12/40). Tumor dimensions were described in 31 dogs. Measurements along the widest axis of the tumor were <4 cm (6/31), 4–6 cm (15/31), and >6 cm (10/31). The mean tumor length along the widest axis was 5.4 cm (SD ± 2.4).

The surgical intent was reported as wide (24/40 [60%]) or marginal (15/40 [37.5%]) or was not specified (1/40, 2.5%). The surgical margin width was provided in 24 cases. Surgical margins used were 0.5–1 cm (4/24), 1.5–2.0 cm (14/24), and 2.5–3.0 cm (6/24).

3.4 | Surgical complications

Dogs that experienced perioperative complications (intraoperative, 9/40 [22.5%]; postoperative, 14 of 40 [35%]) were categorized by the surgical procedure performed (Table 1).

No intraoperative complications were reported in 31 cases. Minor intraoperative complications occurred in 6 dogs (6/40 [15%]), and major intraoperative complications were reported in 3 (3/40, 7.5%). All 3 dogs that experienced major intraoperative complications developed septic peritonitis, which resulted in 2 revision surgeries (1) or euthanasia (2).

No postoperative complications were reported in 26 cases. Six dogs (6/40 [15%]) experienced minor postoperative complications. Major postoperative complications were reported in 8 dogs (8/40 [20%]) and included septic peritonitis (4), cardiopulmonary arrest (2), prolonged clinical signs consistent with ileus, and/or pancreatitis (2) that ultimately resulted in owners electing euthanasia (Table 1).

3.5 | Histologic findings

Histologic diagnoses included gastric adenocarcinoma in situ (2/40) and gastric adenocarcinoma (38/40), with 1 dog having both a gastric adenocarcinoma and an intestinal adenocarcinoma of the distal duodenum removed during the same

TABLE 1 Perioperative complications in dogs undergoing surgical resection for gastric adenocarcinoma

Complication severity	Dogs	Intraoperative (n = 9)	Postoperative (n = 14)	Survival, d
Partial Gastrectomy				
Major complications	1		CPA	2
	2	Spillage gastric contents	Septic peritonitis	1
	3	Inadvertent stab incision into small bowel	Septic peritonitis (intestinal R&A site dehiscence)	190
	4		Septic peritonitis (NSAID-induced duodenal perforation)	2
	5		Gastric stasis; pancreatitis	15
			CPA	2
Minor complications	6	Minor hemorrhage[a]		
	7	Major hemorrhage[a]		43
	8		Hypertension	274
	9	Minor hemorrhage[a]		177
	10		Hyporexia; soft stool	132
Billroth Type I				
Major complications	11		Pancreatitis	16
Minor complications	12	Hypertension	Ascending cholangiohepatitis; pancreatitis	71
	13	Major hemorrhage[a]; 2nd degree AV block		49
	14		Severe pancreatitis; intermittent hypoglycemia	258
	15		Pulled out gastrostomy tube	183
Subtotal Gastrectomy				
Major complications	16	Convert from PG to subtotal gastrectomy	Septic peritonitis (surgical site dehiscence)	13
Minor complications	17	Minor hemorrhage[a]	Vomiting	93

Abbreviations: AV, atrioventricular; CPA, cardiopulmonary arrest; NSAID, nonsteroidal anti-inflammatory drug; PG, partial gastrectomy; R&A, resection and anastomosis.
[a]Hemorrhage: major, requiring blood transfusion; minor, self-limiting hemorrhage.

surgery. For the 38 cases of gastric adenocarcinoma, 15 cases were categorized according to the World Health Organization (WHO) criteria for histologic grade[33] (Table 2). Other histologic features included the presence of vascular invasion and degree of gastric wall invasion (Table 2).

Histologic assessment of surgical margins was available for 39 dogs. The histologic status of the surgical margins was considered either complete (20/39) or incomplete (19/39). For the 24 dogs that had tumors removed with a wide excision, 16 dogs (16/24 [66.7%]) were reported to have complete margins, and 8 dogs (8/24 [33.3%]) were reported to have incomplete margins. For the 15 dogs in which a marginal excision was performed, histologic margins were considered complete in 4 dogs (4/15 [26.7%]), incomplete in 10 dogs (10/15 [66.7%]), and not specified for 1 dog. The surgical margin width was quantitated in 24 cases; however, a correlation between the completeness of tumor excision was not observed. When 0.5–1-cm margins (n = 4) were taken, histological margins were reported as complete in 2 dogs (2/4) and incomplete in the others (2/4). When 1.5–2.0-cm surgical margins (14) were performed, the margin status was considered complete in 12 dogs (12/14) and incomplete in 2 dogs (2/14). Finally, 6 dogs had gastric masses removed with 2.5–3-cm margins; the histologic assessment was considered complete in 3 dogs (3/6) and incomplete in the other 3 (3/6).

Evidence of metastatic disease at the time of surgery was histologically confirmed in 18 dogs (18/40 [45%]). The location of metastatic spread included regional lymph nodes (14/18 dogs), mesentery (3/18 dogs), and 1 dog with liver and regional lymph node involvement. This included 11 dogs (11/40 [27.5%]) that had locoregional metastasis (lymph nodes [8], mesentery [2], lymph node and liver [1]) at the time of surgery that had not been detected on preoperative imaging. In 11 dogs in which preoperative abdominal imaging results suggested the possibility of metastatic disease (lymph node [10], mesentery [1]), metastasis was histologically confirmed in 7 dogs (lymph node [6], mesentery [1]), lymph node biopsy showed no evidence of metastasis in 1 dog, and no report of lymph node sampling was documented in the other 3 dogs.

TABLE 2 Histologic features in dogs with gastric adenocarcinoma

Histologic Features		Cases, n (%)
WHO histologic subtype, n = 15	Tubular	2 (13.3)
	Signet-ring cell	6 (40)
	Mucinous	5 (33.3)
	Undifferentiated	2 (13.3)
Degree of gastric wall invasion, n = 18	Gastric adenocarcinoma in situ	2 (11.1)
	Submucosal invasion	1 (5.5)
	Muscularis invasion	3 (16.7)
	Transmural invasion	12 (66.7)
Vascular or lymphatic invasion, n = 22	Yes	18 (81.8)
	No	4 (18.1)

Abbreviation: WHO, World Health Organization.

3.6 | Adjuvant therapy

Nineteen dogs (19/40 [47.5%]) received single or combination adjuvant chemotherapy including maximum tolerated dose (MTD) chemotherapy (12), metronomic chemotherapy (2), a tyrosine kinase inhibitor (8), and palliative intracavitary chemotherapy to treat metastatic bicavitary effusion (1). The efficacy of specific chemotherapeutic protocols could not be analyzed because of the variation in drug, dose, and frequency used in each case (Table 3).

Maximum tolerated dose chemotherapy protocols included either a single agent or a combination of the following drugs: carboplatin (n = 6), gemcitabine (2), carboplatin/gemcitabine (1), doxorubicin (2), doxorubicin/cyclophosphamide (1), mitoxantrone (1), and carboplatin/5-fluorouracil (1). Dosing and protocols were variable and clinician-dependent, but, of the 12 dogs that received MTD chemotherapy, 8 completed their protocols. Cessation of therapy occurred because of disease progression in 2 dogs, and a delay in treatment because of adverse side effects occurred in the other 2 dogs. Two dogs received metronomic cyclophosphamide (12.5 mg/m^2 orally every other day and 15 mg/m^2 orally once daily) without reporting any adverse events. Toceranib (1.5–3.4 mg/kg orally every Monday/Wednesday/Friday), was administered in 8 dogs. Treatment was terminated shortly after initiation of therapy in 3 dogs because of adverse effects. Toceranib was well tolerated in 2 cases in which it was used continuously until disease progression was noted. Reasons for termination of treatment were not reported in the other dogs, but no adverse effects were noted.

3.7 | Clinical outcome

Mean duration of follow-up was 239 days (range, 1–1902). Overall median PFI was 54 days (95% CI 0–223). Local recurrence was confirmed in 3 dogs by endoscopy (n = 2) and necropsy (1). Local recurrence was suspected in another 9 dogs on the basis of abdominal imaging (3) and recurrence of clinical signs (6). Metastasis was present at the time of surgery in 18 of 40 (45%) dogs. New or progressive metastasis was confirmed or suspected in 10 dogs during the follow-up period. Three of these dogs also had evidence of concurrent local recurrence. Metastatic progression was diagnosed by imaging in 6 cases, by abdominocentesis in 3 cases, and by imaging confirmed with abdominocentesis in 1 case. Metastatic sites included

TABLE 3 Adjuvant chemotherapy in 19 dogs with gastric adenocarcinoma

Dog	Adjuvant therapy	Dose & frequency	Complications	ST, d
1	Carboplatin/5-FU	Carboplatin: 275 mg/m^2 IV, 1 dose single agent, then carboplatin/5-FU: 200 mg/m^2/150 mg/m^2 IV every 3 weeks × 5/5 doses	None	553, still alive
2	Carboplatin	280 mg/m^2 IV every 3 weeks × 5/6 intended doses	Grade 1 lethargy, vomiting, diarrhea Grade 2 neutropenia	272
3	Carboplatin	300 mg/m^2 IV every 3 weeks × 4/4 doses	Grade 1 neutropenia after 3rd dose	93
4	Carboplatin	300 mg/m^2 IV every 3 weeks × 4/4 doses	Grade 1 diarrhea	383, still alive
5	Carboplatin Toceranib[a]	Carboplatin: 285 mg/m^2 IV every 3 weeks × 6/6 doses Toceranib: 2.5 mg/kg MWF × 3 months	Grade 3 neutropenia at day 19—delay	354
6	Carboplatin Mitoxantrone	Carboplatin: 240 mg/m^2 IV × 1 dose Mitoxantrone: 5 mg/m^2 IV every 3 weeks × 6/6 doses	Grade 1 elevation in creatinine—switched to mitoxantrone	190
7	Gemcitabine/carboplatin Toceranib[a]	Week 1 - Gemcitabine/carboplatin: 57 mg/m^2/285 mg/m^2 IV Week 2 - Gemcitabine: 57 mg/m^2 IV × 4/4 cycles Toceranib: 3.3 mg/kg orally MWF	Neutropenia—delay of treatment Grade 2 thrombocytopenia—switched to toceranib	564
8	Carboplatin Cyclophosphamide Doxorubicin	Carboplatin: 300 mg/m^2 every 3 weeks × 4/4 doses Cyclophosphamide: 15 mg/m^2 daily × 2 months Doxorubicin: (dose not reported) every 3 weeks × 3 doses	None	274
9	Toceranib Cyclophosphamide	Toceranib: 1.7 mg/kg orally MWF Cyclophosphamide: 12.5 mg/m^2 orally every other day	Grade 2 anorexia on toceranib—1 week rest	1902
10	Doxorubicin Cyclophosphamide	Week 1 doxorubicin: 27 mg/m^2 IV Weeks 2 & 3 cyclophosphamide: 222 mg/m^2 orally divided over 2 days × 2/5 intended cycles	None	101
11	Doxorubicin	30 mg/m^2 IV every 3 weeks × 4/4 doses	Grade 2 anorexia	177
12	Gemcitabine	222 mg/m^2 IV × 1 dose	None	71
13	Gemcitabine	675 mg/m^2 IV every 2 weeks × 4/4 doses	Grade 1 lethargy	97
14	Toceranib	1.7 mg/kg orally MWF	None	280
15	Toceranib	2.7 mg/kg orally × 2 doses	Grade 2 diarrhea—cessation	403
16	Toceranib	3 mg/kg orally MWF	None	135
17	Toceranib	1.5 mg/kg orally × 2 doses	Grade 1 lethargy—cessation	49
18	Toceranib	3.4 mg/kg orally MWF	Grade 2 diarrhea	132, still alive
19	Intracavitary mitoxantrone	5.5 mg/m^2 diluted 1:1 in 0.9% NaCl, then again in 1 mL/4.5 kg	None	311

Abbreviations: 5-FU, 5-fluorouracil; MWF, Monday/Wednesday/Friday; ST, survival time.
[a]Toceranib started after cytotoxic chemotherapy.

regional lymph nodes (4), mesentery (4), abdominal body wall (1), spleen (1), ureter (1), bladder (1), and ulnar diaphysis (1). Four dogs presented with peritoneal effusion (4), 1 of which had concurrent pleural effusion.

Overall, 35 dogs died or were euthanized, and 5 dogs were censored in the survival analysis. The MST for uncensored dogs was 178 days (95% CI 71–311; range, 1–1902; Figure 1). The overall 1-year survival rate was 17.5%. The 5 dogs that had been censored were still alive at the time of writing, with overall survival times ranging from 153 to 553 days. Survival analysis included 9 dogs that died or were euthanized for reasons unrelated to gastric neoplasia. This included 6 dogs that either died or were euthanized because of complications 1–16 days after surgery. Thus, the survival to discharge for dogs in this study was 85% (34/40), with an MST of 190 days. Three dogs experienced prolonged survival times and died of unrelated gastric carcinoma 258, 1902, and 1443 days after surgery. For the 26 dogs that experienced tumor-related deaths, 18 were the result of local recurrence, and 8 resulted from metastasis.

According to univariable analysis results, the only factors associated with overall survival time were experiencing an intraoperative complication (n = 9, $P = .005$), experiencing a postoperative complication (n = 14, $P = .03$), and administration of adjuvant chemotherapy (n = 19, $P = .03$). Histologic features such as degree of transmural invasion and vascular invasion could not be evaluated for prognostic significance because of too few cases. However, the 2 dogs with adenocarcinoma in situ died of causes unrelated to gastric carcinoma at 258 and 1443 days after surgery, and the 1 dog with mural invasion limited to the submucosa was still alive 153 days after surgery. In addition, the 4 dogs that had no evidence of vascular/lymphatic invasion were either still alive at 132 and 153 days or had protracted survival times of 553 and 1443 days.

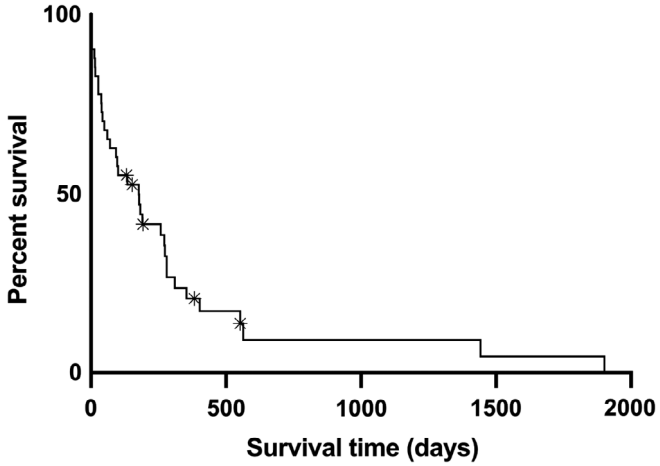

FIGURE 1 Kaplan–Meier survival curve estimating overall survival time for all causes in 40 dogs that underwent surgical resection of gastric adenocarcinoma. Day 0 designates the day of surgery. Asterisks represent censored observations

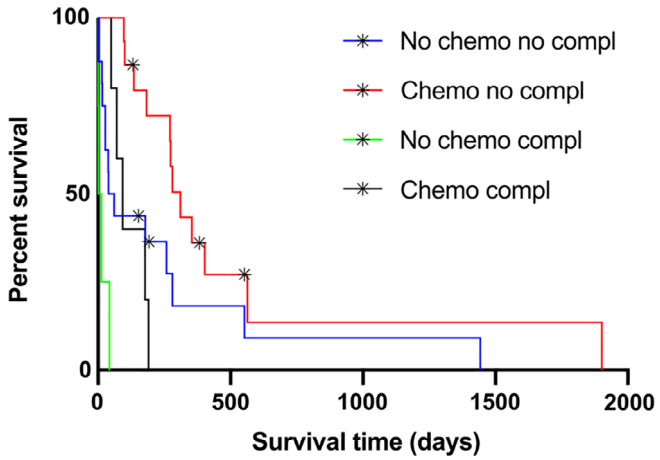

FIGURE 2 Kaplan–Meier survival curves estimating overall survival time for all causes in dogs receiving surgery with or without adjuvant chemotherapy (chemo) and, within those populations, whether an intraoperative complication occurred. Day 0 designates the day of surgery. Asterisks represent censored observations

According to multivariable analysis results, experiencing an intraoperative complication (n = 9) was associated with an increased risk of death (HR 6.1 [95% CI 1.8–21, P = .003]), and receiving adjuvant chemotherapy (n = 19) was correlated with an improved survival (HR 0.3 [95% CI 0.1–0.8; P = .02]; Figure 2).

4 | DISCUSSION

The present study provides information on the largest case series to date of dogs surgically treated for gastric carcinoma. The MST of these dogs (178 days) considerably exceeds the MST of 72 days extrapolated from previously published cases.[1,4,7,10-29] Among these, the 2 largest case series[4,16] included 10 dogs with an MST of 72 days and 6 dogs in which 5 did not live past 63 days. The small samples in both studies likely created a bias to the overall reported survival times, illustrating the value of our larger case series. The MST of 178 days is approximately twice as long as the reported survival time (<3 months) for dogs managed conservatively, which demonstrates the beneficial role of surgery in the treatment of dogs with gastric carcinoma.[1,4,6]

As hypothesized, most cases in this study did not experience perioperative complications. The dehiscence rate (2/40 dogs) and incidence of major postoperative complications (8/40 dogs) were comparable to existing literature.[4,9,12,16] In a previous study[9] of 24 dogs treated with Billroth I, surgical site dehiscence occurred in 2 dogs, and postoperative pancreatitis and aspiration pneumonia were noted in 3 dogs each. In a similar publication,[12] major postoperative complications included acute kidney injury, congestive heart failure, bile duct transection, gastric stasis, and incisional dehiscence and were reported in 6 of 28 dogs undergoing Billroth I. The majority of the dogs in our study that underwent Billroth I (8/9 dogs) did not experience a major postoperative complication, and none developed dehiscence. In a study[16] of 10 dogs with gastric carcinoma that were treated with either partial distal gastrectomy or Billroth I, postoperative morbidity was low and limited to postprandial discomfort, vomiting, and diarrhea in 3 dogs. In combination with the aforementioned published case series,[9,12,16] our findings support the role of surgery in the multimodal management of dogs with gastric carcinoma.

Prognostic factors identified as influencing survival included intraoperative complications and administration of adjuvant chemotherapy. Development of an intraoperative complication was associated with a sixfold increased hazard of death. This finding may reflect tumor location and/or advanced extent of disease requiring more technically complex surgical procedures that may be associated with a higher risk of complication. The fact that intraoperative complications were reported in both of the dogs that underwent a subtotal gastrectomy supports this notion. However, the significance of this finding should be scrutinized. Because various contributors performed data acquisition, individual interpretation of what constituted a perioperative complication may have differed. Although it is unlikely that one would fail to report any major complications, individual subjectivity may have resulted in an over- or underestimate in the number of complications. For example, 3 of the 4 cases contributed from 1 institution listed self-limiting hemorrhage as an intraoperative complication. Cases from other institutions may have also experienced minor intraoperative hemorrhage, but contributors may not have felt the severity warranted stating.

Contrary to our prediction, receiving adjuvant chemotherapy was associated with an improved survival time in this cohort of dogs. This observation, however, should not be interpreted causally because this study is retrospective, and treatments were not randomized. It is possible that a selection bias may have existed in the allocation of treatment or in association with timing of euthanasia, which would have influenced the results. For example, owners that were willing to pursue chemotherapy may have also allowed a longer treatment course before considering euthanasia. Furthermore, whether a reliably effective chemotherapeutic protocol exists could not be deduced from these data because substantial variation existed in the drug, dose, duration, and frequency each dog received. Nevertheless, this preliminary finding justifies additional investigation into the role of chemotherapy in the treatment of canine gastric carcinoma.

An assessment of the minimum surgical margin distance necessary to achieve histologically complete margins for canine gastric carcinoma could not be determined from our data. Current margin recommendations for wide excision of gastric neoplasia in dogs are 1–2 cm of apparently normal tissue around the tumor.[16,34] However, to the best of the authors' knowledge, true surgical safety margins have not been evaluated for canine gastric neoplasia. In the group of dogs that underwent a wide excision, a reasonable proportion (8/24 [33.3%]) had incompletely excised tumors. This finding suggests that the prescribed 1–2-cm margins may not be adequate. In humans with gastric carcinoma, surgical margins have a significant effect on patient survival, and recommendations are dependent on the histologic subtype.[34] For the diffuse type of gastric carcinoma, recommended margins are greater than 5 cm, and, for the intestinal type, 2–3 cm is suggested.[34]

Unfortunately, histologic features could not be assessed for meaningful associations with outcome because of limited cases and inconsistencies regarding what information was provided by individual pathologists in histopathology reports. In human gastric carcinoma, vascular invasion is one of the few histologic characteristics that has reliably predicted tumor behavior and survival, independent of clinical stage.[35,36] Although this variable could not be evaluated in our study population, it is noteworthy that the 4 cases with no evidence of vascular invasion had protracted survival times. On a similar note, prolonged survival times were observed in the 3 cases in which depth of tumor invasion was confined to the gastric mucosa or submucosa. In man, the WHO classification for histologic subtyping[33] has prognostic significance, wherein signet-ring cell and mucinous and undifferentiated subtypes are considered to have a less favorable prognosis compared with tubular or papillary subtypes.[37-39] There is some evidence to support this to be the case in dogs as well. In 1 study,[40] researchers found that dogs with less well-organized, diffuse or signet-ring cell type tumors experienced earlier metastasis. Additional studies are warranted to evaluate surgical and histologic margins as well as the association between histologic characteristics and biologic behavior in dogs with gastric tumors.

In this study, the presence of metastasis at the time of surgery was confirmed histologically in 18 of 40 (45%) dogs. However, because surgical procedures were not standardized and, in most cases, lymph node sampling was not routinely performed, a more accurate rate of nodal metastasis at diagnosis could not be determined. Based on the predictable pattern of metastatic spread with gastric adenocarcinoma, when it arises from glandular epithelium and spreads via intramural or submucosal lymphatics to regional lymph nodes,[41] evaluation of regional lymph nodes at the time of surgery should be considered for accurate staging. In human medicine, regional lymphadenectomy is the standard of care, demonstrating a benefit both for staging purposes and for improving outcome in patients with gastric carcinoma.[42,43] In addition, for early gastric cancer patients in whom disease is confined to the submucosa or muscularis layers without spread to regional lymph nodes, it is routine for surgeons to use sentinel lymph node mapping to guide dissection.[44] Thus, it may be valuable for veterinary surgeons to consider regional lymph node excision guided by sentinel lymph node mapping, as previously described with peritumoral injection of methylene blue.[45] At a minimum, routine lymph node sampling at the time of surgical resection may be worthwhile because it is well known that micrometastasis can be present in lymph nodes that are normal in size.[46]

The short median PFI of 54 days suggests that it may be appropriate to consider regular monitoring with abdominal imaging every 1–2 months after surgery for gastric carcinoma. The first progression event, when it was reported, was either local recurrence or metastatic spread to regional lymph nodes, mesentery, or confined to the peritoneal cavity. None of the dogs had evidence of pulmonary metastasis at the time of diagnosis, and there was no evidence of distant metastatic spread to the thoracic cavity except for bicavitary metastatic effusion that developed in 1 dog. These findings would suggest that follow-up thoracic radiographs may be of low yield in dogs with gastric carcinoma after surgery unless disease is advanced.

Limitations of this study include the small sample because of the rare occurrence of this condition. Because of the inherent nature of multi-institutional retrospective studies, other limitations include variation in the surgical procedures, which were performed by multiple surgeons with differences in surgical technique. Surgical margins, surgical implants (suture type and whether staples were used), perioperative treatments, adjuvant therapies, and follow-up times were not standardized. The disparity across these variables precludes more in-depth evaluation

of these factors with respect to outcomes. All histopathologic samples would ideally have been reviewed by a single pathologist, and postmortem examination would have been performed on all dogs.

Although dogs treated with surgical resection of gastric carcinoma lived longer in our study compared with previously reported studies, only 17.5% of dogs survived 1 year after surgery, justifying a guarded long-term prognosis. Adjuvant chemotherapy was associated with a longer survival, but a randomized controlled prospective trial is required to establish a chemotherapeutic protocol. Results from this study may be used to improve counseling of owners regarding prognosis of candidates for surgical excision of gastric carcinoma.

CONFLICT OF INTEREST

The authors declare no conflicts of interest related to this report.

ORCID

Carlos Henrique de Mello Souza https://orcid.org/0000-0003-4771-7829
Brandan G. Wustefeld-Janssens https://orcid.org/0000-0001-8458-1735
Michelle L. Oblak https://orcid.org/0000-0001-8489-4643
Laura E. Selmic https://orcid.org/0000-0001-6695-6273

REFERENCES

1. Fonda D, Gualtieri M, Scanziani E. Gastric carcinoma in the dog: a clinicopathological study of 11 cases. *J Small Anim Pract.* 1989; 30:353-360.
2. Patnaik AK, Hurvitz AI, Johnson GF. Canine gastrointestinal neoplasms. *Vet Pathol.* 1977;14:547-555.
3. Sullivan M, Lee R, Fisher EW, Nash AS, McCandlish IA. A study of 31 cases of gastric carcinoma in dogs. *Vet Rec.* 1987;120:79-83.
4. Swann HM, Holt DE. Canine gastric adenocarcinoma and leiomyosarcoma: a retrospective study of 21 cases (1986–1999) and literature review. *J Am Anim Hosp Assoc.* 2002;38:157-164.
5. Seim-Wikse T, Jörundsson E, Nødtvedt A, et al. Breed predisposition to canine gastric carcinoma - a study based on the Norwegian canine cancer register. *Acta Vet Scand.* 2013;55:25.
6. Berg P, Rhodes WH, O'Brien JB. Radiographic diagnosis of gastric adenocarcinoma in a dog. *J Am Vet Rad Soc.* 1964;5:47-53.
7. Sellon RK, Bissonnette K, Bunch SE. Long-term survival after total gastrectomy for gastric adenocarcinoma in a dog. *J Vet Intern Med.* 1996;10:333-335.
8. Sautter JH, Hanlon GF. Gastric neoplasms in the dog: a report of 20 cases. *J Am Vet Med Assoc.* 1975;166:691-696.
9. Eisele J, McClaran JK, Runge JJ, et al. Evaluation of risk factors for morbidity after pylorectomy and gastroduodenostomy in dogs. *Vet Surg.* 2010;39:261-267.
10. Olivieri M, Gosselin Y, Sauvageau R. Gastric adenocarcinoma in a dog: six-and-one-half month survival following partial gastrectomy and gastroduodenostomy. *J Am Anim Hosp Assoc.* 1984;20:78-82.
11. Elliott GS, Stoffregen DA, Richardson DC, Blevins WE, Richardson RC. Surgical, medical, and nutritional management of gastric adenocarcinoma in a dog. *J Am Vet Med Assoc.* 1984;185: 98-101.
12. Walter MC, Matthiesen DT, Stone EA. Pylorectomy and gastroduodenostomy in the dog: technique and clinical results in 28 cases. *J Am Vet Med Assoc.* 1985;187:909-914.
13. McDonald AE. Primary gastric carcinoma of the dog: review and case report. *Vet Surg.* 1978;3:70-73.
14. Dorn AS, Anderson NV, Guffy MM, Cho DY, Leipold HW. Gastric carcinoma in a dog. *J Small Anim Pract.* 1976;17:109-117.
15. Douglas SW, Hall LW, Walker RG. The surgical relief of gastric lesions in the dog: report of seven cases. *Vet Rec.* 1970;86: 743-746.
16. Gualtieri M, Monzeglio MG, Scanziani E. Gastric neoplasia. *Vet Clin North Am Small Anim Pract.* 1999;29:415-440.
17. Murray M, Robinson PB. Primary gastric neoplasia in the dog: a clinicopathological study. *Vet Rec.* 1972;91:474-479.
18. Penninck DG, Moore AS, Gliatto J. Ultrasonography of canine gastric epithelial neoplasia. *Vet Rad Ultrasound.* 1998;39:342-348.
19. Pollock S, Wagner B. Gastric adenocarcinoma or linitis plastica in a dog. *Vet Med Small Anim Clin.* 1973;68:139-142.
20. Lingeman CH, Garner FM, Taylor DO. Spontaneous gastric adenocarcinoma: a review. *J Nat Cancer Inst.* 1971;47:137-153.
21. Sinclair CJ, Jones BR, Verkerk G. Gastric carcinoma in a bitch. *NZ Vet J.* 1979;27:16-18.
22. Wright RP. Malignant gastric ulcer associated with adenocarcinoma of the gastric fundus in a dog. *Vet Med Small Anim Clinic.* 1981;76:845-848.
23. Hutter VH, Köppel E, Schönbauer M. Diagnose und operative Behandlung eines Adenokarzinoms des Magens beim Hund. *Kleintierpraxis.* 1982;27:271-276.
24. Beck C, Slocombe RF, O'Neill T, Holloway SA. The use of ultrasound in the investigation of gastric carcinoma in a dog. *Aust Vet J.* 2001;79:332-334.
25. Stanclift RM, Gilson SD. Use of cisplatin, 5-fluorouracil, and second-look laparotomy for the management of gastrointestinal adenocarcinoma in three dogs. *J Am Vet Med Assoc.* 2004;225: 1412-1417.
26. Nielsen C, Anderson GM. Metastasis of gastric adenocarcinoma to the abdominal wall following placement of a gastrostomy tube in a dog. *Can Vet J.* 2005;46:641-643.
27. Nakasawa H, Itoh Y, Tani K, et al. Partial gastroduodenectomy and gastrojejunostomy in a dog with pyloric adenocarcinoma. *Jpn J Vet Anesth Surg.* 2011;42:29-34.
28. von Babo V, Eberle N, Mischke R, et al. Canine nonhematopoietic gastric neoplasia: epidemiologic and diagnostic characteristics in 38 dogs with postsurgical outcome of five cases. *Tierarztl Prax Ausg K Kleintiere Heimtiere.* 2012;40:243-249.
29. Lee HC, Kim JH, Jee CH, et al. A case of gastric adenocarcinoma in a shih tzu dog: successful treatment of early gastric cancer. *J Vet Med Sci.* 2014;76:1033-1038.
30. Veterinary Cooperative Oncology Group. Veterinary Cooperative Oncology Group—Common Terminology Criteria for Adverse Events (VCOG-CTCAE) following chemotherapy or biological antineoplastic therapy in dogs and cats v1.1. *Vet Comp Oncol.* 2016;14:417-446.

31. Enneking WF, Spanier SS, Goodman MA. A system for the surgical staging of musculoskeletal sarcoma. *Clin Orthop Relat Res.* 1980;2003(415):4-18.
32. Bennett TC, Matz BM, Henderson RA, et al. Total prostatectomy as a treatment for prostatic carcinoma in 25 dogs. *Vet Surg*. 2018; 47:367-377.
33. Head KW, Cullen JM, Dubielzig RR, et al. *Histological Classification of Tumors of the Alimentary System of Domestic Animals, Second Series.* Vol. X. Washington, DC: Armed Forces Institute of Pathology, American Registry of Pathology, and the World Health Organization Collaborating Center for Worldwide Reference on Comparative. *Oncology*. 2003;89-93.
34. Hugen S, Thomas RE, German AJ, Burgener IA, Mandigers PJJ. Gastric carcinoma in canines and humans, a review. *Vet Comp Oncol.* 2016;15:692-705.
35. Solci E, Klersy C, Mastracci L, et al. A combined histologic and molecular approach identifies three groups of gastric cancer with different prognosis. *Virchows Arch.* 2009;455:197-211.
36. Gabbert HE, Meier S, Gerharz CD, Hommel G. Incidence and prognostic significance of vascular invasion in 529 gastric cancer patients. *Int J Cancer.* 1991;49:203-207.
37. Hass HG, Smith U, Jager C, et al. Signet ring cell carcinoma of the stomach is significantly associated with poor prognosis and diffuse gastric cancer (Lauren's): single-center experience of 160 cases. *Onkologie.* 2011;34:682-686.
38. Liu L, Wang ZW, Ji J, et al. A cohort study and meta-analysis between histopathological classification and prognosis of gastric carcinoma. *Anticancer Agents Med Chem.* 2013;13:227-234.
39. Oliveira C, Seruca R, Carneiro F. Hereditary gastric cancer. *Best Pract Res Clin Gastroenterol.* 2009;23:147-157.
40. Janke L, Carlson CS, St Hill CA. The novel carbohydrate tumor antigen C2-O-sLe x is upregulated in canine gastric carcinomas. *Vet Pathol.* 2010;47:455-461.
41. Morrison WB. Nonlymphomatous cancers of the esophagus, stomach, and intestines. In: Morrison WB, ed. *Cancer in Dogs and Cats: Medical and Surgical Management*. Jackson, WY: Teton NewMedia; 2002:527-533.
42. Jiang L, Yang KH, Chen Y, et al. Systematic review and meta-analysis of the effectiveness and safety of extended lymphadenectomy in patients with resectable gastric cancer. *Br J Surg.* 2014;101: 595-604.
43. Songun I, Putter H, Kranenbarg EM, Sasako M, van de Velde CJ. Surgical treatment of gastric cancer: 15-year follow-up results of the randomised nationwide Dutch D1D2 trial. *Lancet Oncol.* 2010; 11:439-449.
44. Kitagawa Y, Takeuchi H, Takagi Y, et al. Sentinel node mapping for gastric cancer: a prospective multicenter trial in Japan. *J Clin Oncol.* 2013;31:3704-3710.
45. Brissot HN, Edery EG. Use of indirect lymphography to identify sentinel lymph node in dogs: a pilot study in 30 tumours. *Vet Comp Oncol.* 2017;15:740-753.
46. Williams LE, Packer RA. Association between lymph node size and metastasis in dogs with oral malignant melanoma: 100 cases (1987-2001). *J Am Vet Med Assoc.* 2003;222:1234-1236.

How to cite this article: Abrams B, Wavreille VA, Husbands BD, et al. Perioperative complications and outcome after surgery for treatment of gastric carcinoma in dogs: A Veterinary Society of Surgical Oncology retrospective study of 40 cases (2004–2018). *Veterinary Surgery*. 2019;48:923–932. https://doi.org/10.1111/vsu.13239