Received: 3 November 2018 | Revised: 10 January 2019 | Accepted: 11 January 2019
DOI: 10.1111/vco.12456

Veterinary and Comparative Oncology WILEY

ORIGINAL ARTICLE

Outcomes and prognostic variables associated with primary abdominal visceral soft tissue sarcomas in dogs: A Veterinary Society of Surgical Oncology retrospective study

Dan Linden[1] | Julius M. Liptak[2] | Arathi Vinayak[3] | Janet A. Grimes[4] | Maninder Sandey[1] | Whitney Smiley[5] | Brad M. Matz[1]

[1]Department of Clinical Sciences for Matz, Auburn University College of Veterinary Medicine, Auburn, Alabama

[2]VCA Canada, Alta Vista Animal Hospital, Ottawa, Ontario, Canada

[3]VCA West Coast Specialty and Emergency Animal Hospital, Fountain Valley, California

[4]Department of Small Animal Medicine and Surgery for Grimes, University of Georgia College of Veterinary Medicine, Athens, Georgia

[5]Smiley Data Analytics, Philadelphia, Pennsylvania

Correspondence
Brad M. Matz, Auburn University College of Veterinary Medicine, 1220 Wire Road, Auburn, AL 36849.
Email: bmm0007@auburn.edu

Primary abdominal visceral soft tissue sarcomas (STSs) are rare tumours in dogs with little information available on outcomes. The goal of this retrospective, multi-institutional study was to describe the common tumour types, location and prognostic factors associated with primary abdominal visceral STSs. Medical records were searched for dogs with primary abdominal visceral STSs at six institutions and were retrospectively reviewed. Tumours were graded using the previously described grading scheme for STSs of the skin and subcutis when information in the histopathology report contained adequate details. Forty-two dogs were included in the study. Five dogs had grade I tumours, 11 had grade II and 15 had grade III tumours. The most common tumour type was leiomyosarcoma (38.1%). The most common tumour locations were the spleen (47.6%) and small intestine (23.8%). The local recurrence rate was low (4.7%). Metastasis was present at the time of surgery in 23.8%, and the overall metastatic rate was 40.4%. Mitotic index of ≥9 was associated with significantly shorter survival time (MST 269 days) compared with a mitotic index of <9 (MST not reached). The MST for grade I STSs was not reached, was 589 days for grade II and 158 days for grade III. Dogs with grade III tumours were more likely to develop metastatic disease. Neither location of the primary tumour nor the histologic subtype was associated with survival time. Histologic grading of abdominal visceral STSs using the previously described scheme is prognostic and should be provided on histopathology reports.

KEYWORDS
dogs, oncology, sarcoma, soft tissue sarcoma, visceral

1 | INTRODUCTION

Soft tissue sarcomas (STSs) are a heterogenous group of tumours that originate from connective tissues such as muscle, adipose, fascia or fibrous tissue.[1,2] These tumours can arise from any anatomic site; however, they most commonly arise from the skin or subcutaneous tissue. Grading of STSs of the skin and subcutis rely on three major variables: necrosis, differentiation and mitotic count index, which has recently been standardized to mitotic index per 2.37 mm.[3,4] A cumulative score of these three variables allows for a total tumour score and consistent grading of STSs using a scale of low (grade I), intermediate (grade II) or high (grade III). [4] Both risk of recurrence and metastatic potential has been highly correlated with grade of cutaneous and subcutaneous STSs in dogs.[2,4,5]

Primary abdominal visceral STSs are uncommon, and there are little data that describe these tumours in dogs. Leiomyosarcomas are the second most common small intestinal tumour in dogs and have a predilection site for the jejunum and cecum.[6,7] However, leiomyosarcomas and gastrointestinal stromal cell tumours (GISTs) can be difficult to differentiate without immunohistochemical markers. A recent review of previously diagnosed gastrointestinal leiomyomas and leiomyosarcomas led to reclassification of the majority of these tumours to GISTs.[8,9] The largest study of gastrointestinal leiomyosarcomas to date included 44 dogs with a histologic diagnosis of leiomyosarcoma; however, these results must be interpreted with caution as neither c-

 © 2019 John Wiley & Sons Ltd

kit nor DOG-1 staining was performed to differentiate GISTs from leiomyosarcoma.[6] The outcomes and prognostic variables of dogs with splenic liposarcomas were recently reported.[10] The authors of this study determined that histologic grade and evidence of metastasis at the time of surgery were negative prognostic indicators. However, it is unknown whether the grading scheme for STSs is applicable to visceral tumours, as this grading system was originally used to describe only tumours of the skin and subcutis.[4] In addition, previous studies of splenic stromal sarcomas have shown that survival times are strongly correlated with mitotic index and that a mitotic index of ≥9 is associated with poorer outcomes.[11] Leiomyosarcomas and liposarcomas account for the majority of primary abdominal visceral STSs in people.[12,13] In people, retroperitoneal STSs occur with greater frequency than intra-peritoneal STSs.[13] In humans, there is a high rate of local recurrence for intra-abdominal STSs ranging from 41% to 50%.[13] Surgical margins, tumour grading, histologic subtype and tumour size are prognostic for humans with intra-abdominal STSs.[12,14–19] There is limited information regarding primary abdominal visceral STSs in dogs. One study which evaluated grade III STSs included eight dogs with primary abdominal visceral STSs found comparable survivals to splenic hemangiosarcoma,[20] but there is little other information available on these tumours in the literature.

The purposes of this study were to (a) determine the common locations for primary abdominal visceral STSs, (b) determine variables associated with outcomes of primary abdominal visceral STSs and (c) to determine whether the grading scheme used for skin and subcutaneous STSs would be prognostic for primary abdominal visceral STSs.

2 | MATERIALS AND METHODS

This study was initiated by requesting case submissions from Veterinary Society of Surgical Oncology (VSSO) members. Medical records from contributing institutions were searched for dogs with a diagnosis of a primary abdominal visceral STS from 1 January 2005 to 31 July 2017. Dogs were included if they had a histopathologic diagnosis of primary STSs of the abdominal viscera (including but not limited to stomach, small intestine, urinary bladder, kidney, ureter, cecum, colon, liver, spleen); dogs diagnosed with extraskeletal osteosarcoma, histiocytic sarcoma and GISTs were excluded, as these tumours are not considered part of the STS group. Dogs with a diagnosis of leiomyosarcomas were included if immunohistological staining was performed with c-kit or DOG-1 to rule out GIST. Dogs included in the study were required to have pre-operative three-view thoracic radiographs, histopathology reports available for review, surgery reports available for review and a minimum follow-up time of 3 months. Data retrieved from the medical record included the following: sex, breed, age, weight, clinical signs and presenting complaint, date of presentation, date of surgery, haematologic and biochemistry abnormalities, pre-operative cytology or histopathology, pre-operative ultrasound and radiographic findings, clinical staging, surgical procedures performed, evidence of metastasis at the time of surgery, histopathologic diagnosis and surgical margin assessment, intra-operative and postoperative surgical complications (classified as minor if further surgical intervention was not required and major if life-threatening or requiring further surgical intervention), postoperative adjuvant therapy (agent used, dose and number of doses), date of detection of local recurrence and/or distant metastasis and date and cause of death. Tumour size was determined from the surgical or histopathologic report. If only two dimensions were recorded, cubic size was estimated by multiplying these two dimensions by their mean value.

Dogs were excluded from the study if they had metastatic STSs of the abdominal viscera with the primary tumour at a non-visceral site based on surgical and histopathologic findings.

Histopathology reports were reviewed by a board-certified anatomic pathologist and assigned a grade according to the previously described grading scheme for STSs of the skin and subcutaneous tissues.[4] If adequate information was not present in the histopathology report to allow for grading, a grade was not assigned. Oncologic outcomes measured were disease-free interval (DFI) and median survival time (MST). The DFI was defined as the time from the surgical intervention until the date of first evidence of local recurrence or metastasis. Survival time was defined as the time between surgical intervention and the time of death. The cause of death was determined from the medical records or follow-up contact with the referring veterinarian. The cause of death was classified as either tumour related or unrelated. Dogs for which the cause of death was unknown were presumed to have died or been euthanized for tumour-related causes. Dogs that died because of non-tumour-related conditions or were lost to follow-up were censored from survival analysis.

2.1 | Statistical analysis

Descriptive statistics for signalment, history, preoperative and postoperative data were generated and reported as a median and range. For all comparisons regarding categorical outcomes, a Fischer's exact test was used to determine significance. Disease-free interval (DFI) and MST were estimated from Kaplan-Meier survival analysis. A log-rank test was used to compare survival analysis for tumour grade, presence of metastatic disease, mitotic index, completeness of excision, impact of adjuvant chemotherapy and tumour subtype. For analysis of the impact of tumour location, tumours were grouped as gastrointestinal, hepatosplenic and genitourinary. Tumour mitotic index was stratified to <9 and ≥ 9 and evaluated separately. $P \leq 0.05$ was considered significant. Statistical software (SAS, 9.4, SAS, Cary, North Carolina) was used for descriptive, categorical and Kaplan-Meier survival analysis.

3 | RESULTS

3.1 | Signalment

Forty-two dogs met the inclusion criteria. The median body weight was 22.1 kg (range: 4.6-40.4 kg). The median age at diagnosis was 9.4 years (range: 3.9-17.9). There were 16 spayed female, two intact female, 19 neutered male and five intact male dogs. Breeds were mixed (n = 11), Labrador retriever,[6] boxer,[3] golden retriever,[2] German shepherd dog,[2] beagle[2] and one each of catahoula, miniature schnauzer, jack russell terrier, flat coated retriever, dachshund, German

shorthaired pointer, English bulldog, Cairn terrier, Wheaten terrier, weimaraner, cocker spaniel, English springer spaniel, bichon frise, Australian cattle dog, standard poodle and Maltese.

3.2 | Clinical signs

Clinical signs at the time of presentation included decreased appetite (n = 14, 33.3%), vomiting/diarrhoea (n = 12, 28.6%), lethargy (n = 11, 26.2%), abdominal distension (n = 10, 23.8%), polyuria/polydipsia (n = 4, 9.5%), weight loss (n = 4, 9.5%), pollakiuria/hematuria (n = 3, 7.1%), melena (n = 3, 7.1%), weakness (n = 2, 4.7%) and nausea (n = 1, 2.4%) (Table 1). Presence of an abdominal mass was an incidental finding in six dogs.

3.3 | Preoperative diagnostic tests

Data from serum biochemistry and haematology tests were available in 39 dogs. Biochemistry abnormalities included hypoalbuminaemia (n = 9, 21.4%), elevated alkaline phosphatase (ALP) (n = 6, 14.2%), decreased blood urea nitrogen (BUN) (n = 2, 4.7%), hypocalcaemia (n = 2, 4.7%), elevated alanine aminotransferase (ALT) (n = 2, 4.7%), hyperbilirubinaemia (n = 2, 4.7%), hypernatraemia (n = 3, 7.1%), hyperchloraemia (n = 1, 2.4%), hyperglycaemia (n = 1, 2.4%), hyperphosphataemia (n = 1, 2.4%) and hypercholesterolemia (n = 1, 2.4%). Haematologic abnormalities included anaemia (n = 15, 40.5%), neutrophilia (n = 12, 28.6%), thrombocytosis (n = 3, 7.1%), lymphopaenia (n = 2, 4.7%), thrombocytopaenia (n = 2, 4.7%), monocytosis (n = 2, 4.7%) and eosinophilia (n = 2, 4.7%). One dog had an abnormal coagulogram (2.4%). Preoperative thoracic radiographs were performed in all dogs, and none had evidence of pulmonary metastatic disease. Pre-operative cytology was performed in 17 cases. Aspirates were performed of the small intestine,[6] liver,[3] spleen,[3] kidney,[1] pylorus,[1] cecum,[1] bladder,[1] and ureter.[1] A cytologic diagnosis of or suggestive of sarcoma was diagnosed in nine dogs, carcinoma in three dogs, malignant neoplasia in one dog and a non-diagnostic sample in four dogs. A pre-operative incisional biopsy was performed in one dog and was consistent with a leiomyosarcoma. Endoscopic enteric biopsy was performed in one dog which was consistent with normal mucosa. Abdominal ultrasound was performed preoperatively in 33 dogs. Abdominal ultrasound findings related to the tumour were a mass (29), free abdominal fluid,[9] lymphadenopathy,[3] partial intestinal obstruction[2] and hydroureter/hydronephrosis.[1] A computed tomography scan was performed in one dog and identified a large splenic mass.

TABLE 1 Biochemistry and haematologic abnormalities in dogs with abdominal visceral soft tissue sarcomas

Abnormality	Number of cases
Hypoalbuminaemia	9 (21.4%)
Elevated ALP	6 (14.2%)
Decreased BUN	2 (4.7%)
Hypocalcaemia	2 (4.7%)
Elevated ALT	2 (4.7%)
Hyperbilirubinaemia	2 (4.7%)
Hypernatraemia	3 (7.1%)
Hyperchloraemia	1 (2.4%)
Hyperglycaemia	1 (2.4%)
Hyperphosphataemia	1 (2.4%)
Hypercholesterolaemia	1 (2.4%)
Anaemia	15 (40.5%)
Neutrophilia	12 (28.6%)
Thrombocytosis	3 (7.1%)
Lymphopaenia	2 (4.7%)
Thrombocytopaenia	2 (4.7%)
Monocytosis	2 (4.7%)
Eosinophilia	2 (4.7%)
Abnormal coagulogram	1 (2.4%)

3.4 | Surgical procedures and complications

The surgical procedure performed was dictated by the location of the mass and surgeon preference. Procedures performed included complete splenectomy (n = 21), small intestinal resection and anastomosis,[10] nephroureterectomy,[2] marginal resection of pyloric masses with subsequent omentalization,[2] pylorectomy with a cholecystoenterostomy and gastrostomy tube placement[1] partial cystectomy,[1] partial cystectomy and neoureterocystostomy,[1] typhlectomy,[1] partial liver lobectomy and splenectomy,[1] complete liver lobectomy with partial splenectomy,[1] removal of a falciform mass[1] and removal of an omental mass.[1] A liver biopsy was concurrently performed in 14 dogs, lymphadenectomy performed concurrently in nine cases (six dogs with splenic masses and three dogs with small intestinal masses), and an omental biopsy was performed in one dog. A prophylactic gastropexy was performed in four dogs, and derotation/gastropexy of a gastric dilatation and volvulus in one case.

Two dogs died of cardiac arrest at 1 and 2 days postoperatively. The first dog had a small intestinal mass and underwent resection and anastomosis, and the second dog had a splenic mass and underwent splenectomy with lymph node biopsy. There were three minor intraoperative surgical complications including mild haemorrhage (n = 2) and ischaemic injury to the omentum.[1] Postoperatively, there was one minor complication (superficial incisional infection) and one major complication (septic peritonitis). Revision surgery was performed in the dog with septic peritonitis to repair a partial dehiscence of the resection and anastomosis site and the dog survived to discharge.

3.5 | Histopathologic diagnosis and tumour characteristics

Histopathologic evaluation was performed in all dogs. Primary visceral abdominal STSs were found in the spleen,[20] small intestine,[10] liver,[4] pylorus,[3] bladder,[2] and one each in the kidney, cecum and ureter (Table 2). There was no difference in survival time when organ of origin was compared ($P = 0.250$). The most common histopathologic diagnosis was leiomyosarcoma (n = 16, 38.1%). Other histopathologic diagnoses included STSs without subtype (n = 12, 28.6%), splenic stromal sarcoma (n = 8, 19%), fibrosarcoma (n = 4, 9.5%), myxosarcoma (n = 1, 2.4%) and peripheral nerve sheath tumour (n = 1, 2.4%). Histologic grade was assigned from the histopathology report per the

TABLE 2 Summary of location, type and grade of primary abdominal viscera soft tissue sarcomas in dogs

Tumour location	Number of cases	Tumour types	Grade
Spleen	20	Stromal sarcoma = 8	I = 1, II = 3, III = 4
		STS = 5	II = 1, III = 3, Unknown = 1
		Leiomyosarcoma = 3	I = 1, II = 1, Unknown = 1
		Fibrosarcoma = 2	Unknown = 2
		Myxosarcoma = 1	III = 1
		PNST = 1	III = 1
Small intestines	10	Leiomyosarcoma = 7	I = 1, II = 2, III = 3, Unknown = 1
		STS = 2	II = 1, Unknown = 1
		Fibrosarcoma = 1	Unknown = 1
Liver	4	STS = 4	II = I, III = 2, Unknown = 1
Pylorus	3	Leiomyosarcoma = 2	I = 1, Unknown = 1
		STS = 1	II = 1
Bladder	2	Leiomyosarcoma = 2	I = 1, Unknown = 1
Kidney	1	Fibrosarcoma	Unknown = 1
Cecum	1	Leiomyosarcoma	II = 1
Ureter	1	Leiomyosarcoma	III = 1

Abbreviations: STS, soft tissue sarcoma; PNST, peripheral nerve sheath tumour.

previously described grading scheme when adequate information was available.[4] A histologic grade was assigned in 31 tumours: grade I (n = 5, 16.1%), grade II (n = 11, 35.5%) and grade III (n = 15, 48.4%). Mitotic index was evaluated independent of grade. Fourteen dogs had a mitotic index of ≤9, and 17 dogs had a mitotic index >9. Histopathologic margin status was available for 29 dogs. A complete histopathologic margin was obtained in 18 dogs and incomplete margins were present in 11 dogs. The surgical margin was not associated with survival times (P = 0.262.) The size of the tumour was recorded in 22 dogs. The median tumour size was 437.5 cm^3 (range: 10.6-18 000). Tumour size was not associated with survival times (P = 0.176).

4 | ADJUVANT THERAPY

Seven dogs received adjuvant chemotherapy. Protocols included doxorubicin (n = 3), alternating doxorubicin and cyclophosphamide (n = 1), epirubicin and cyclophosphamide (n = 1), chlorambucil (n = 1) and doxorubicin and mitoxantrone (n = 1). Protocols and dosing varied; however, five dogs completed the prescribed chemotherapy protocol. Of the seven dogs treated with chemotherapy, five dogs had grade III STSs, one dog had a grade II STS and histologic grade was unable to be determined for one dog. No dogs were treated with adjuvant radiation therapy. Of the seven dogs treated with chemotherapy, all dogs had metastatic disease present at the time of surgery. There was an association between the administration of adjuvant chemotherapy and a decrease in survival times (P = 0.038). Dogs receiving adjuvant chemotherapy had a (MST) of 153 days compared with 589 days for dogs not treated with adjuvant chemotherapy. When looking at dogs with grade III STSs, there was no difference in MST between dogs that did and did not receive adjuvant chemotherapy (153 and 364 days, respectively).

5 | CLINICAL OUTCOME

Follow-up information was available for 36 dogs; six dogs were lost to follow-up. Twelve dogs were censored from survival analysis. Of the 12 dogs that were censored, nine dogs were still alive at the time of the study and three dogs died of reasons unrelated to their tumours. The median follow-up time for censored patients was 533 days. Metastatic disease was present in 10 (23.8%) dogs at the time of surgery. Eight dogs had a single metastatic site, while two dogs had multiple. The location of the primary tumour for dogs with metastatic disease at the time of surgery included spleen,[8] liver[1] and jejunum.[1] Sites of metastatic disease at the time of surgery included liver (n = 9), omentum,[2] falciform fat,[1] mesentery,[1] and mesenteric lymph node.[1] Of the 10 dogs with metastasis at the time of surgery, six dogs had grade III STSs, one dog had a grade II STS, one dog had a grade I STS and grade was unknown in two dogs. Seven dogs without evidence of metastasis at the time of surgery developed histologically confirmed[2] or suspected[5] as having metastatic disease. Suspected metastatic disease was diagnosed by abdominal ultrasound in four cases and abdominal palpation in one dog. Four dogs had a single site of metastasis, and three dogs had multiple sites. The most common sites of postoperative metastatic disease were the liver,[5] diaphragm,[1] mesocolon,[1] mesenteric lymph node,[1] lungs,[1] kidney,[1] and mesentery.[1] The location of primary abdominal visceral STSs of dogs who developed postoperative metastatic disease were small intestine,[3] spleen,[2] pylorus[1] and ureter.[1] Of the dogs with postoperative metastatic disease, three dogs had grade III STSs, two dogs had grade II STSs, and the grade could not be determined for two dogs. The overall metastatic rate was 40.5%. The overall metastatic rate was 20% for grade I, 27.2% for grade II, and 60% for grade III tumours. Dogs with grade III STSs were more likely to develop metastatic disease (P = 0.001). Median time to metastasis was 147 days (range: 123-563 days). Local recurrence in the liver and small intestine was suspected in two dogs with a DFI of 123 and 148 days, respectively.

The MST for all dogs was 599 days (range: 0->1966 days). When using the histologic grading scheme for cutaneous and subcutaneous STSs, tumour grade was associated with survival time (P = 0. 026). The MSTs for dogs with a grade I, II, and III STSs respectively were, not reached, 589 days (range: 32-1966 days) and 158 days (range: 23-554 days) (Figure 1). When mitotic index was evaluated as a continuous variable, it was not associated with survival time (P = 0.95). Mitotic index ≥9 was associated with a shorter MST (269 days) than a mitotic index of <9 (MST not reached, P = 0.037) (Figure 2). The MST for dogs with metastasis present at the time of surgery was 65 days. Dogs that did not have metastasis present at the time of surgery had a MST of 590 days. Metastatic disease at the time of surgery was associated with a shorter MST (P = 0.0.001). No other variables (primary tumour location, size, histologic subtype, completeness of excision) were associated with survival times.

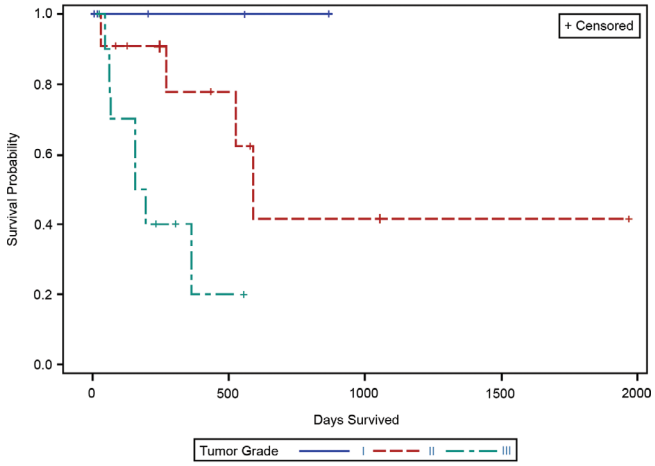

FIGURE 1 A Kaplan-Meier survival curve for dogs with soft tissue sarcomas stratified by tumour grade [Colour figure can be viewed at wileyonlinelibrary.com]

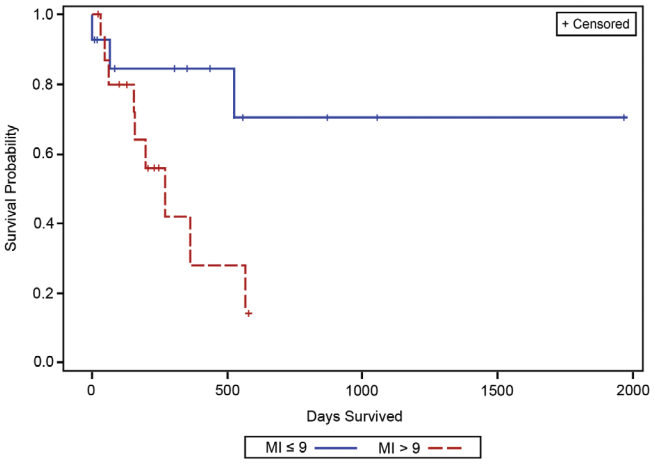

FIGURE 2 A Kaplan-Meier survival curve for dogs with mitotic index ≥9 per 10 high powered field and < 9 per 10 high powered field [Colour figure can be viewed at wileyonlinelibrary.com]

6 | DISCUSSION

STS of the skin and subcutaneous tissues are well described in dogs; however, information on primary abdominal visceral STSs is lacking.[4] In the present study, the most common locations of primary abdominal visceral STSs were the spleen and the small intestine. The most common types of primary abdominal visceral STSs in human medicine are leiomyosarcomas and liposarcomas.[12,13] This was true for the present study with 38.1% of primary abdominal visceral STSs being leiomyosarcomas. While there were low numbers of other histologic subtypes of STSs, there was no difference in outcomes with different histologic subtypes. Similarly, the location of tumour, when grouped as gastrointestinal, hepatosplenic and genitourinary did not impact survival times.

For STSs of the skin and subcutaneous tissues, important prognostic factors include tumour grade, margin of excision and mitotic index.[4] A previous report of non-angiomatous, non-lymphomatous neoplasms of the spleen showed that a mitotic count cutoff of 9 per 10 hpf was a significant prognostic factor.[11] Similarly, in this study, a mitotic index <9 was associated with a significantly better prognosis with a MST not reached compared with 269 days for dogs with abdominal visceral STS with a mitotic index ≥9.

STSs are relatively chemoresistant and administration of cytotoxic chemotherapy has not been shown to prolong survival times.[20] However, the aforementioned study only evaluated the impact of chemotherapy of dogs with higher grade STSs. In addition, this study was underpowered, included tumours often not categorized as STSs (histiocytic sarcoma) and was retrospective in nature, therefore should be interpreted with caution. In the present study, administration of chemotherapy was associated with a shorter survival time. This was likely caused by selection bias, as the majority of dogs treated with chemotherapy had high-grade tumours, and all treated dogs had metastatic disease at the time of diagnosis. Owing to the small sample size of the dogs that received adjuvant chemotherapy and the large difference in MST for the two groups, a power analysis was conducted and determined to be 0.32. Thus, the lack of significance could be because of the low power. The true impact of chemotherapy on outcome was difficult to discern due to the retrospective nature of the study, limited statistical power and lack of standardization of drug, dose and dosing interval.

For dogs with STSs of the skin and subcutaneous tissues, the metastatic potential is grade dependent with reported metastatic rates of <10%, 20% and 41 to 50% for grade I, II and II STS, respectively.[2,4] In the present study, 23.8% of dogs had metastatic disease at the time of surgery. Of the 10 dogs diagnosed with metastasis at the time of the initial surgery, six dogs had grade III tumours. The metastatic rate for high grade STSs in this study was 40.0% at the time of diagnosis and 60.0% overall. This is slightly higher than that reported for high grade STSs of the skin and subcutis. The metastatic rate for grade I and grade II tumours in this study was 20.0% and 27.2%, respectively. These rates are higher than that reported for skin and subcutis.[2,4] It is possible that the higher incidence of metastasis for grade I tumours is a result of the low number included in the study. However, it is possible that primary abdominal visceral STSs have a higher metastatic potential than those of the skin and subcutis. This may warrant treatment with adjuvant cytotoxic chemotherapy. The data reported in this study suggests utility in grading abdominal visceral STSs using the previously described criteria for cutaneous and subcutaneous STSs. Using the previously described criteria appears prognostic for primary abdominal visceral STSs. In human medicine, recurrence rates of primary abdominal visceral STSs are high (41%-50%) despite wide excision.[13] Recurrence was suspected in only two dogs in the current study (4.7%). Owing to the small number of cases with local recurrence, the impact of margin of resection on recurrence was unable to be determined. Metronomic chemotherapy has been suggested to delay the time to recurrence for STSs of the skin and subcutis,[21] however there is no literature to support its use in primary abdominal visceral STSs. The role of metronomic chemotherapy for primary abdominal visceral STSs warrants further investigation.

The grading scheme established for STSs consists of a cumulative score of three factors: mitotic index, differentiation and degree of necrosis.[4] The results of this study support the use of the original grading scheme for primary abdominal visceral STSs to guide prognosis. The overall MST for dogs in the present study was 599 days. Dogs with grade I STSs in the current study had long term survivals with the

MST not reached, while dogs with grade III STSs had a MST of only 158 days.

Limitations of the present study include those inherent to retrospective studies including incomplete medical records, limited case numbers and lack of standardization of treatment and staging tests. In addition, due to the lack of standardization for follow-up, the rate of metastasis and recurrence may have been higher than that recorded in our study.

The results of the study support our hypothesis that the grading scheme previously used for skin and subcutaneous STSs is also prognostic for dogs with primary abdominal visceral STSs and therefore could be used for histopathologic grading. Grade III tumours, a mitotic index of ≥9 and metastasis at the time of surgery are negative prognostic indicators. Future studies are needed to determine the role of adjuvant cytotoxic chemotherapy in canine abdominal visceral STSs. In addition, future studies are needed to better assess the impact of tumour location and histologic subtype on long-term outcome.

ACKNOWLEDGEMENTS

The authors would like to thank Dr. Stephen Atwater and Dr. Megan Cray for their contributions to the manuscript.

CONFLICTS OF INTEREST

The authors declare no conflicts of interest.

ORCID

Brad M. Matz https://orcid.org/0000-0002-6478-9536

REFERENCES

1. Withrow SJ, Vail DM, MacEwen EG. *Withrow & MacEwen's Small Animal Clinical Oncology*. 4th ed. St. Louis, MO: Saunders Elsevier; 2007.
2. Bray JP. Soft tissue sarcoma in the dog–part 1: a current review. *J Small Anim Pract*. 2016;57:510-519.
3. Meuten DJ, Moore FM, George JW. Mitotic count and the field of view area: time to standardize. *Vet Pathol*. 2016;53:7-9.
4. Dennis MM, McSporran KD, Bacon NJ, et al. Prognostic factors for cutaneous and subcutaneous soft tissue sarcomas in dogs. *Vet Pathol*. 2011;48:73-84.
5. McSporran KD. Histologic grade predicts recurrence for marginally excised canine subcutaneous soft tissue sarcomas. *Vet Pathol*. 2009; 46:928-933.
6. Kapatkin AS, Mullen HS, Matthiesen DT, Patnaik AK. Leiomyosarcoma in dogs: 44 cases (1983-1988). *J Am Vet Med Assoc*. 1992;201:1077-1079.
7. Cohen M, Post GS, Wright JC. Gastrointestinal leiomyosarcoma in 14 dogs. *J Vet Intern Med*. 2003;17:107-110.
8. Maas CP, ter Haar G, van der Gaag I, et al. Reclassification of small intestinal and cecal smooth muscle tumors in 72 dogs: clinical, histologic, and immunohistochemical evaluation. *Vet Surg*. 2007;36: 302-313.
9. Russell KN, Mehler SJ, Skorupski KA, Baez JL, Shofer FS, Goldschmidt MH. Clinical and immunohistochemical differentiation of gastrointestinal stromal tumors from leiomyosarcomas in dogs: 42 cases (1990-2003). *J Am Vet Med Assoc*. 2007;230:1329-1333.
10. Gower KL. Splenic liposarcoma in dogs: 13 cases (2002–2012). *J Am Vet Med Assoc*. 2015;247:1404-1407.
11. Spangler WL, Culbertson MR, Kass PH. Primary mesenchymal (nonangiomatous/nonlymphomatous) neoplasms occurring in the canine spleen: anatomic classification, immunohistochemistry, and mitotic activity correlated with patient survival. *Vet Pathol*. 1994;31: 37-47.
12. Bonvalot S, Rivoire M, Castaing M, et al. Primary retroperitoneal sarcomas: a multivariate analysis of surgical factors associated with local control. *J Clin Oncol*. 2009;27:31-37.
13. Liles JS, Tzeng CW, Short JJ, et al. Retroperitoneal and intra-abdominal sarcoma. *Curr Probl Surg*. 2009;46:445-503.
14. Hager S, Makowiec F, Henne K, Hopt UT, Wittel UA. Significant benefits in survival by the use of surgery combined with radiotherapy for retroperitoneal soft tissue sarcoma. *Radiat Oncol*. 2017;12(29):29.
15. Bonvalot S, Miceli R, Berselli M, et al. Aggressive surgery in retroperitoneal soft tissue sarcoma carried out at high-volume centers is safe and is associated with improved local control. *Ann Surg Oncol*. 2010; 17:1507-1514.
16. Stoeckle E, Coindre JM, Bonvalot S, et al. Prognostic factors in retroperitoneal sarcoma: a multivariate analysis of a series of 165 patients of the French Cancer Center Federation Sarcoma Group. *Cancer*. 2001;92:359-368.
17. van Dalen T, Hoekstra HJ, van Geel AN, et al. Locoregional recurrence of retroperitoneal soft tissue sarcoma: second chance of cure for selected patients. *Eur J Surg Oncol*. 2001;27:564-568.
18. Yang JC, Chang AE, Baker AR, et al. Randomized prospective study of the benefit of adjuvant radiation therapy in the treatment of soft tissue sarcomas of the extremity. *J Clin Oncol*. 1998;16:197-203.
19. Gholami S, Jacobs CD, Kapp DS, et al. The value of surgery for retroperitoneal sarcoma. *Sarcoma*. 2009;2009:605840.
20. Selting KA, Powers BE, Thompson LJ, et al. Outcome of dogs with high-grade soft tissue sarcomas treated with and without adjuvant doxorubicin chemotherapy: 39 cases (1996-2004). *J Am Vet Med Assoc*. 2005;227:1442-1448.
21. Elmslie RE, Glawe P, Dow SW. Metronomic therapy with cyclophosphamide and piroxicam effectively delays tumor recurrence in dogs with incompletely resected soft tissue sarcomas. *J Vet Intern Med*. 2008;22:1373-1379.

How to cite this article: Linden D, Liptak JM, Vinayak A, et al. Outcomes and prognostic variables associated with primary abdominal visceral soft tissue sarcomas in dogs: A Veterinary Society of Surgical Oncology retrospective study. *Vet Comp Oncol*. 2019;17:265–270. https://doi.org/10.1111/vco.12456