Splenic liposarcoma in dogs: 13 cases (2002–2012)

Krista L. A. Gower, DVM; Julius M. Liptak, BVSc, MVetClinStud; William T. N. Culp, DVM; Lina Bravo, DVM; Barbara Powers, DVM, PhD; Stephen J. Withrow, DVM

Objective—To describe the clinical signs, diagnostic findings, surgical management, and outcome in dogs with splenic liposarcoma.

Design—Retrospective case series.

Animals—13 client-owned dogs with splenic liposarcoma.

Procedures—Medical and pathology records of dogs with a histopathologic diagnosis of splenic liposarcoma from 2002 to 2012 were reviewed for the following data: clinical signs, CBC, biochemical profile, thoracic and abdominal imaging, surgical management, histologic grade, and outcome (local recurrence, distant metastasis, and survival time). Telephone interviews were conducted with referring veterinarians.

Results—The median survival time (MST) was 623 days (range, 1 to 1,283 days). In 5 dogs that died of splenic liposarcoma, survival times ranged from 42 to 369 days. Metastasis at the time of surgery was a negative prognostic indicator: the MST was 45 days for dogs with metastasis and 767 days for dogs without metastasis. Dogs with grade 1 splenic liposarcoma had a significantly greater MST (1,009 days), compared with dogs with grade 2 or 3 splenic liposarcoma (MST, 206 and 74 days, respectively).

Conclusions and Clinical Relevance—Results confirmed that splenic liposarcoma is a rare differential diagnosis in dogs with a splenic mass. Survival time was influenced by preoperative clinical stage and histologic grade. (*J Am Vet Med Assoc* 2015;247:1404–1407)

Liposarcoma is an uncommon mesenchymal tumor of the skin and subcutis and is rarely found in visceral organs such as the spleen.[1] Most information available regarding liposarcoma is from reports of dogs with cutaneous and subcutaneous liposarcomas.[2] The tumor arises from lipoblasts and is locally invasive. Metastasis is rare, and when it does occur, it is usually to the lungs or abdominal viscera.[1] Splenic liposarcoma is rarely reported, and outcome following treatment has not been conclusively determined.[2–4] A retrospective study[2] of 56 dogs with liposarcoma included 6 dogs with visceral liposarcoma; however, the location of these tumors and survival data were not reported.

Differential diagnoses for dogs with a splenic mass include nodular hyperplasia, hematoma, hemangioma, hemangiosarcoma, lymphoma, and nonangiomatous, nonlymphomatous sarcomas.[5,6] Liposarcoma is categorized as a nonangiomatous, nonlymphomatous sarcoma. Other tumor types belonging to this classification include leiomyosarcoma, osteosarcoma, fibrosarcoma, myxosarcoma, chondrosarcoma, rhabomyosarcoma, malignant fibrous histiocytoma, and undifferentiated sarcoma.[3,4] The prognosis for dogs with nonangiomatous, nonlymphomatous sarcomas is guarded, with MSTs ranging from 75 to 120 days.[3,4] In a study[3] of 57 dogs with nonangiomatous, nonlymphomatous sarcomas (including 3 dogs with splenic liposarcomas), the MST was 2.5 months. Metastasis was a negative prognostic indicator: the MST was 1 month in dogs with metastasis and 9 months in dogs without metastasis.[3] In another report[4] of 87 dogs with nonangiomatous, nonlymphomatous sarcomas (including 2 dogs with splenic liposarcomas), the MST was 4 months and mitotic index > 9 mitotic figures/10 hpfs was found to be a negative prognostic indicator. If there were ≤ 9 mitotic figures /10 hpfs, there was a 40% chance for a prolonged survival time.[4]

The purpose of the study reported here was to describe the clinical signs, physical examination findings, clinical staging results, histologic grade, and outcome in dogs that underwent splenectomy for histologically confirmed splenic liposarcoma. An additional goal was to identify negative prognostic indicators.

Abbreviation

MST	Median survival time

Materials and Methods

Case selection—Members of the Veterinary Society of Surgical Oncology contributed cases to this retrospective study. Medical records from Alta Vista Animal Hospital, Colorado State University Veterinary Teaching Hospital, and University of California-Davis Veteri-

From Alta Vista Animal Hospital, 2616 Bank St, Ottawa, ON K1T 1M9, Canada (Gower, Liptak, Bravo); the Department of Surgical and Radiological Sciences, School of Veterinary Medicine, University of California-Davis, Davis, CA 95616 (Culp); and the Flint Animal Cancer Center and Diagnostic Laboratory, Department of Veterinary Clinical Sciences, College of Veterinary Medicine and Biomedical Sciences, Colorado State University, Fort Collins, CO 80523 (Powers, Withrow). Address correspondence to Dr. Liptak (jliptak@avah.on.ca).

nary Medical Teaching Hospital were reviewed for dogs with splenic liposarcoma from 2002 to 2012. Inclusion criteria included splenectomy, histopathology report confirming liposarcoma, and complete medical records. Exclusion criteria included splenic tumors other than liposarcoma and dogs with splenic liposarcoma in which follow-up information was not available.

Procedure—Data collected included abnormalities in history and physical examination such as inappetence, weakness, and a palpable abdominal mass; abnormalities detected on CBC, serum biochemical analysis, and urinalysis; results of diagnostic imaging (abdominal radiography or ultrasonography and 3-view thoracic radiography); surgical findings; adjunctive treatment; histopathologic diagnosis and histologic grade; and outcome (local recurrence, distant metastasis, and survival time). A histologic grading system described for canine soft tissue sarcomas was used to determine histologic grade.[7] Times from the date of surgery to local recurrence, distant metastasis, and death were determined. If these outcome data were not available from the medical records, then the referring veterinarian or owner was called for this information.

Statistical analysis—Kaplan-Meier analysis was used to determine MST. Log-rank analysis was performed to determine whether inappetence, hypoalbuminemia, increased alkaline phosphatase activity, monocytosis, neutrophilia, anemia, metastasis at the time of diagnosis, or histologic grade had a significant effect on survival time. Dogs that were lost to follow-up or died of non–tumor-related causes were censored from analysis. Tumor-related causes of death were defined as death or euthanasia as a result of local recurrence or metastasis of splenic liposarcoma. Analyses were performed with the aid of a software program.[a] Values of $P < 0.05$ were considered significant.

Results

Thirteen dogs with histologically confirmed splenic liposarcoma were included in the study. Ten of these dogs were males (4 sexually intact and 6 neutered) and 3 were spayed females. The mean ± SD age was 11.7 ± 2.9 years (median, 12.0 years; range, 5 to 16 years). The mean body weight was 21.1 ± 10.2 kg (46.4 ± 22.4 lb), and the median body weight was 23.8 kg (52.4 lb) with a range of 4.5 to 33.2 kg (9.9 to 73.0 lb). The breeds represented included Labrador Retriever (n = 3) and 1 each of Miniature Poodle, Border Collie, Golden Retriever, Boxer, Lhasa Apso, Basenji, Papillon, German Shepherd Dog, Beagle, and Staffordshire Bull Terrier. History and clinical signs included inappetence in 4 dogs, abdominal distension in 4 dogs, weakness in 3 dogs, and weight loss, tenesmus, vomiting, and diarrhea in 1 dog each.

One dog was evaluated because of osteoarthritis, and an abdominal mass was palpated incidentally. Physical examination findings included a palpable abdominal mass in 11 dogs, abdominal distension and fluid wave in 1 dog, and signs of abdominal discomfort in 1 dog.

Seven dogs had a regenerative anemia. Mean Hct in the anemic dogs was 31% (median, 33%; range, 25% to 35%). Three of the anemic dogs had mature neutrophilia and monocytosis, 1 had neutrophilia with a left shift, and 1 had lymphopenia and monocytosis. Five of 13 dogs had hypoalbuminemia (range, 1.5 to 2.4 g/dL; reference range, 2.6 to 4.0 g/dL). Alkaline phosphatase activity was mildly elevated (≤ 2 times the upper limit of the reference range) in 5 of 13 dogs, and moderately elevated (> 2 times the upper limit of the reference range) in 1 dog (range in these 6 dogs, 198 to 614 U/L; reference range values varied between laboratories). One of 6 dogs with increased alkaline phosphatase activity had hepatic metastasis, and another had cholangiohepatitis. One of 13 dogs had an elevated BUN concentration (27 mg/dL; reference range, 6 to 25 mg/dL) but a serum creatinine concentration within reference range. Prothrombin time and partial thromboplastin time were assessed in 2 of 13 dogs, and partial thromboplastin time was elevated in 1 of these dogs (105 seconds; reference range, 59 to 87 seconds).

Thoracic radiography was performed in 12 of 13 dogs, and metastasis was not radiographically apparent in any dog. Abdominal radiography was performed in 10 of 13 dogs, and a mass was detected in all 10 dogs. Abdominal ultrasonography was performed in 11 of 13 dogs, and a single large splenic mass was imaged in all 11 dogs. On ultrasonographic images, the diameter of the mass was measured as > 5 to 10 cm in 2 dogs, > 10 to 15 cm in 3 dogs, > 15 to 20 cm in 3 dogs, and > 20 cm in 3 dogs. From ultrasonographic examination, the location of the mass within the spleen was recorded for 5 dogs. In 4 dogs, the mass was in the splenic body, and in 1 dog, the mass was in the head of the spleen. Ultrasound-guided fine-needle aspiration of the splenic mass was performed in 3 of the 5 dogs. This revealed a cytologic diagnosis of sarcoma in 2 dogs and mixed inflammation in 1 dog. On ultrasonographic evaluation, liver nodules were noted in 1 dog, and these were confirmed as metastatic disease following histologic evaluation of a liver biopsy specimen.

Splenectomy was performed in all 13 dogs; tumor size was measured for 6 dogs. The mean tumor size was 640.7 cm^2 (median, 378.0 cm^2; range, 107.4 to 2,500.0 cm^2). Three dogs had liver metastasis confirmed by histologic evaluation of a liver biopsy specimen obtained at the time of surgery. Two of the 3 dogs died of metastatic disease 42 and 47 days after surgery, and 1 died of unrelated disease 3 days after surgery. Other surgical and histopathologic findings included a biliary cyst and adrenal gland tumor in 1 dog, cholangiohepatitis in 1 dog, and lymph node metastasis from a cutaneous mast cell tumor in 1 dog. All dogs had a histopathologic diagnosis of splenic liposarcoma. There were 7 grade 1 tumors, 3 grade 2 tumors, and 3 grade 3 tumors. Mitotic index was ≤ 5 mitotic figures/10 hpfs in 11 dogs, > 5 to 29 mitotic figures/10 hpfs in 1 dog with a grade 3 liposarcoma, and ≥ 30 mitotic figures/10 hpfs in another dog with a grade 3 liposarcoma. No dogs received adjunctive therapy. One dog received interferon as a treatment for a concomitant metastatic cutaneous mast cell tumor.

Cytologic confirmation of local recurrence in the splenic bed was reported in 1 dog with a grade 1 splenic liposarcoma and metastatic mast cell tumor at 144 days after surgery. Two dogs with nonmetastatic disease at the time of surgery later died of suspected hepatic me-

tastasis. One of these dogs was evaluated 185 days after surgery with hemoabdomen, and suspected hepatic metastasis was visualized ultrasonographically. The second dog underwent exploratory abdominal surgery for a suspected prostatic abscess 369 days after surgery. Multiple large hepatic nodules were seen during surgery, but these were not assessed. Both dogs were euthanized, and cytologic or histologic evaluation of liver specimens was not performed to confirm metastasis in either dog.

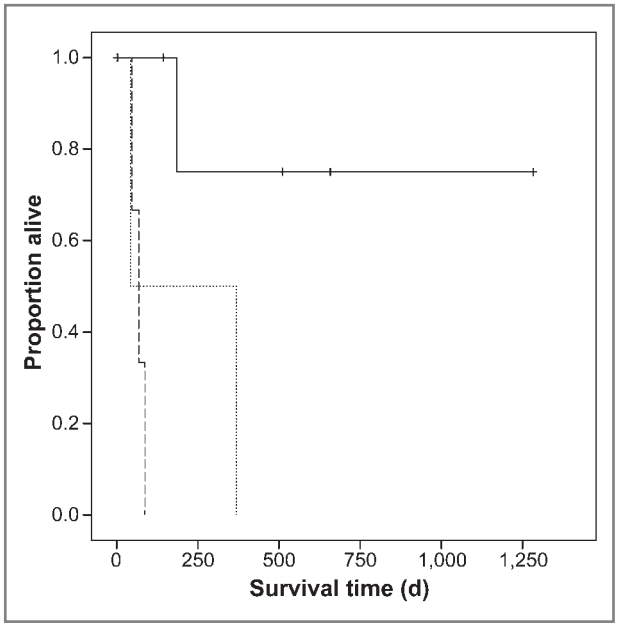

Figure 1—Kaplan-Meier survival curves for 8 dogs with grade 1 (7 dogs; solid line), grade 2 (2 dogs; dotted line), and grade 3 (3 dogs; dashed line) splenic liposarcoma. The dog with a grade 1 splenic liposarcoma had a significantly longer MST, compared with dogs with grade 2 (P = 0.017) and grade 3 (P = 0.033) tumors. Seven dogs were censored (6 dogs with grade 1 and 1 dog with grade 2 splenic liposarcoma).

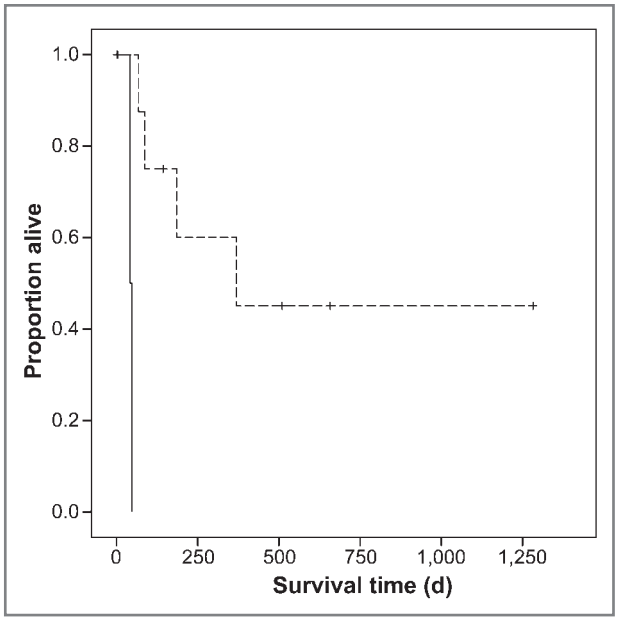

Figure 2—Kaplan-Meier survival curves for dogs with splenic liposarcoma with (3 dogs; solid line) or without (10 dogs; dashed line) metastasis at the time of diagnosis. Dogs with metastasis at the time of diagnosis had a significantly (P = 0.001) shorter MST (45 days), compared with dogs without metastasis (767 days). Seven dogs were censored (1 dog with metastasis and 6 dogs without metastasis).

Twelve dogs died and 1 dog was still alive and disease free 1,283 days after surgery. Death was disease related in 5 dogs. Death occurred from 42 to 369 days after surgery. Four of the 5 dogs with hepatic metastasis died because of metastatic disease. Two dogs with hepatic metastasis at the time of surgery were euthanized 42 and 47 days later because of metastatic progression. Two dogs developed hepatic metastasis after surgery and were euthanized 185 and 365 days after surgery. One dog died at home 87 days after surgery, and this was suspected to be a disease-related death.

Seven dogs died or were euthanatized because of unrelated diseases, and 1 dog was still alive. The cause of death and postoperative survival times for the 7 dogs were gastric dilatation-volvulus (survival time, 1 day), unknown for 2 dogs (both dogs were discharged from the hospital and doing well at the time of discharge; 3 days each), behavioral and gait changes (68 days), mast cell tumor (144 days), osteoarthritis (510 days), and anorexia and anxiety (658 days). One dog was alive at 1,283 days.

The overall MST was 623 days (range, 1 to 1,283 days). In 5 dogs that died of splenic liposarcoma, the survival time ranged from 42 to 369 days. The MST of dogs with grade 1, 2, and 3 tumors was 1,009 days (range, 3 to 1,283 days), 206 days (range, 1 to 369 days), and 74 days (range, 47 to 87 days), respectively. Disease-related deaths were reported in 1 of 7 dogs with grade 1 splenic liposarcomas, 2 of 3 dogs with grade 2 splenic liposarcomas, and 2 of 3 dogs with grade 3 splenic liposarcomas. Dogs with grade 1 splenic liposarcomas had a significantly longer MST, compared with dogs with grade 2 (P = 0.033) and 3 (P = 0.017) tumors (**Figure 1**). Dogs with metastasis at the time of surgery had a significantly (P = 0.001) shorter MST (45 days), compared with dogs without metastasis at surgery (767 days; **Figure 2**).

Discussion

The present study was the first to provide data on dogs with splenic liposarcoma. The signalment was similar to dogs with other types of splenic tumors.[3] Clinical signs were nonspecific. Physical examination revealed an abnormality during abdominal palpation in all 13 dogs: 11 dogs had a palpable mass, 1 dog had a fluid wave, and 1 dog had signs of abdominal pain. These findings are not specific to splenic liposarcoma, but they are an indication to recommend further abdominal imaging. A splenic mass was found on abdominal imaging (radiography or ultrasonography) in all dogs of this study. In all cases, a solitary mass was found ranging in size from 5 to > 20 cm in diameter. A solitary mass was an expected finding in dogs with a primary splenic tumor; however, most splenic liposarcomas were large. The differential diagnoses in dogs with a solitary splenic mass include hematoma, hemangioma, hemangiosarcoma, and nonangiomatous, nonlymphomatous sarcomas (including liposarcoma).[5,6]

Anemia was detected in 7 of the 13 dogs. Anemia was not associated with survival time, but it is interesting that so many dogs were anemic, considering that rupture of the tumor was not noted in any case. The cause of the anemia was not evaluated, but anemia could be associated with chronic disease, intermittent splenic hemorrhage, or an unrelated issue. Mild to moderate anemia is frequently seen in dogs with hemangiosarcoma due to splenic hemorrhage.[8] Acanthocytes, schizocytes, and thrombocytopenia are also commonly seen in these dogs. Thrombocytopenia was not reported in any of the dogs with splenic liposarcoma. Red blood cell morphology was not described in this report, so no comment can be made on the presence or absence of acanthocytes or schizocytes in dogs with splenic liposarcoma. Given the frequency of anemia in the present study, splenic liposarcoma should be included in the differential diagnosis list of dogs with anemia and a splenic mass.

All dogs in this study underwent splenectomy. The overall MST was 623 days. Diagnosis of a grade 2 or 3 splenic liposarcoma was found to be a negative prognostic indicator, compared with diagnosis of grade 1 tumors. Dogs with grade 2 and 3 tumors had MSTs of 206 and 74 days, respectively, compared with 1,009 days in dogs with grade 1 splenic liposarcomas. A histologic grading scheme described for canine soft tissue sarcomas was used to grade liposarcomas.[7] In this scheme, among other criteria, grade 1 tumors had 0 to 9 mitotic figures/10 hpfs, whereas grade 2 and 3 tumors had 10 to 19 mitotic figures/10 hpfs and > 19 mitotic figures/10 hpfs, respectively. The significantly greater MST for dogs with grade 1 splenic liposarcomas is consistent with the findings of Spangler et al,[4] who showed a significantly better survival time in dogs with nonangiomatous, nonlymphomatous sarcomas with 0 to 9 mitotic figures/10 hpfs. Mitotic index was not assessed statistically in the present study because only 1 dog had > 10 mitotic figures/10 hpfs. The overall MST of 623 days in the present study is higher than the MST of 75 to 120 days reported in dogs with nonangiomatous, nonlymphomatous sarcomas.[3,4]

Dogs did not receive adjuvant therapy for splenic liposarcoma in the present study. One dog received interferon as a part of the treatment for a concomitant mast cell tumor. Given the poor prognosis in dogs with grade 2 and 3 splenic liposarcomas, consideration of adjuvant chemotherapy is warranted. There is a paucity of data for adjuvant therapy of nonangiomatous, nonlymphomatous sarcomas. A study by Selting et al[9] showed no difference in survival times between dogs with visceral and nonvisceral grade 3 soft tissue sarcomas treated with surgery alone and surgery with doxorubicin chemotherapy. Dogs with hemangiosarcoma have a survival time of 19 to 89 days with surgery alone and 141 to 179 days with surgery and a doxorubicin-based chemotherapy protocol.[1] Adjuvant chemotherapy should be considered in dogs with grade 2 and 3 splenic liposarcomas on the basis of the high metastatic rate and poor survival times in these dogs.

Three of 13 dogs had metastasis at the time of diagnosis in the present study. Hepatic metastasis was found in 3 dogs at the time of diagnosis and was suspected after surgery in 2 dogs, but pulmonary metastasis was not detected in any dog. Metastatic disease was reported in dogs with all histologic grades, and metastasis occurred in the liver in all cases; hence, abdominal ultrasonography is recommended to monitor for hepatic metastasis at regular intervals after surgery. Metastasis at the time of diagnosis had a significant negative impact on prognosis. Dogs with metastasis had an MST of 45 days, compared with 767 days in dogs without metastasis ($P = 0.001$). This finding is consistent with reports of nonangiomatous, nonlymphomatous splenic sarcomas, for which the MST was 30 days in dogs with metastasis and 270 days in dogs without metastasis.[3]

Histologic review was performed by the same pathologist in 10 of 13 cases. This is a limitation of the study; review by a single pathologist in all cases would have been preferable. Other limitations of this study included the small population and retrospective study design. However, this was the largest report to date on splenic liposarcoma in dogs. Given the rarity of the tumor, a large prospective study is likely not possible.

Splenic liposarcoma is a rare tumor but should be included as a differential diagnosis in dogs with a solid solitary splenic mass. Dogs with grade 2 and 3 splenic liposarcomas and dogs with distant metastasis at the time of diagnosis have a poor prognosis. Chemotherapy should be considered as an adjuvant therapy in dogs with splenic liposarcomas.

a. SPSS Statistics Desktop, version 22.0.0, IBM-SPSS, Chicago, Ill.

References

1. Withrow SJ, Vail DM, Page RL. *Small animal clinical oncology*. 5th ed. St Louis: Elsevier Saunders, 2013;359.
2. Baez JL, Hendrick MJ, Shofer FS, et al. Liposarcomas in dogs: 56 cases (1989–2000). *J Am Vet Med Assoc* 2004;224:887–891.
3. Weinstein MJ, Carpenter JL, Mehlhaff Schunk CJ. Nonangiogenic and nonlymphomatous sarcomas of the canine spleen: 57 cases (1975–1987). *J Am Vet Med Assoc* 1989;195:784–788.
4. Spangler WL, Culbertson MR, Kass PH. Primary mesenchyal (nonangiomatous/nonlymphomatous) neoplasms occurring in the canine spleen: anatomic classification, immunohistochemistry, and mitotic activity correlated with patient survival. *Vet Pathol* 1994;31:37–47.
5. Neer TM. Clinical approach to splenomegaly in dogs and cats. *Compend Contin Educ Vet* 1996;18:35–46.
6. Spangler WL, Kass PH. Pathologic factors affecting postsplenectomy survival in dogs. *J Vet Intern Med* 1997;11:166–171.
7. Kuntz CA, Dernell WS, Powers BE, et al. Prognostic factors for surgical treatment of soft-tissue sarcomas in dogs: 75 cases (1986–1996). *J Am Vet Med Assoc* 1997;211:1147–1151.
8. Ng CY, Mills JN. Clinical and haematological features of haemangiosarcoma in dogs. *Aust Vet J* 1985;62:1–4.
9. Selting KA, Powers BE, Thompson LJ, et al. Outcome of dogs with high-grade soft tissue sarcomas treated with and without adjuvant doxorubicin chemotherapy: 39 cases (1996–2004). *J Am Vet Med Assoc* 2005;227:1442–1448.