The Diagnosis and Surgical Management of Intracardiac Quill Foreign Body in a Dog

Daniel Joseph Santiago Nucci, DVM, Julius Liptak, BVSc, MVetClinStud, FACVSc, DACVS, DECVS

ABSTRACT

A dog was referred to Alta Vista Animal Hospital with a porcupine quill penetrating the right ventricle. The presenting complaint was tachypnea and dyspnea secondary to bilateral pneumothorax. Computed tomography revealed bilateral pneumothorax without evidence of quills. A median sternotomy was performed and the quill was removed. The dog recovered uneventfully. Quill injuries are common in dogs; however, intracardiac quill migration is rare. Dogs without evidence of severe cardiac injury secondary to intracardiac foreign bodies may have a good prognosis. (*J Am Anim Hosp Assoc* 2016; 52:73–76. DOI 10.5326/JAAHA-MS-6332)

Introduction

Intracardiac foreign bodies are not commonly reported in veterinary medicine. To date, only a handful of reports exist describing their diagnosis and management. These have included gastrointestinal migration of ingested sewing needles and barbeque skewers, Kirschner wire migration from previous fracture fixations, metallic projectile foreign bodies, and intravascular migration of catheter fragments.[1–8] Despite the propensity for porcupine quills to migrate, intracardiac quill foreign bodies are exceedingly rare in veterinary medicine.

Quilling injuries from encounters with porcupines are a relatively common phenomenon in North America.[9,10] In a study conducted by the Western College of Veterinary Medicine, quilling injuries represented 2.1% of total new hospital admissions between 1998–2002.[9] Animals that sustain quill injuries often have numerous quills embedded in their skin that frequently breakoff at the surface.[9] Due to the barbed tips on the quill, they have a tendency to migrate into deeper tissue, posing a significant risk to vital organs. For this reason, the veterinary community has observed a wide variety of quill-related injuries. Examples of quilling injuries have included reports of quill migration to the eyes, necessitating enucleations; to the lungs, causing pneumothorax and pleural effusion; to the joints, leading to septic arthritis and secondary endocarditis; to the vertebrae and spinal canal, causing progressive neck pain; and to the brain, causing severe, uncontrollable encephalitis and, eventually, death.[9–14] Although quilling injuries are common in North America, migration of a porcupine quill into the heart has only been reported once previously.[8] The purpose of this case report is to describe the diagnosis, management, and prognosis associated with an intracardiac quill foreign body in a dog.

Case Report

A 5 yr old female spayed beagle was presented to Alta Vista Animal Hospital for evaluation of pneumothorax. Prior to presentation, over 100 quills had been removed from the body of the dog by the referring veterinarian. She was discharged after removal of the quills, but represented to the referring veterinarian 4 days later for tachypnea and dyspnea. Thoracic radiographs revealed pneumothorax. Thoracocentesis was performed and approximately 1 L of air was aspirated from the thoracic cavity after which the respiratory status of the dog immediately improved. The dog was then transferred to Alta Vista Animal Hospital for further workup and treatment.

On admission to Alta Vista Animal Hospital, the dog was bright and alert. Physical examination revealed mildly muffled bronchovesicular sounds dorsally. Cardiac auscultation was within normal limits and the only other abnormality noted on physical

From the Alta Vista Animal Hospital, Ottawa, Ontario, Canada.

Correspondence: djsnucci@gmail.com (D.J.S.N.)

CT, computed tomography

© 2016 by American Animal Hospital Association

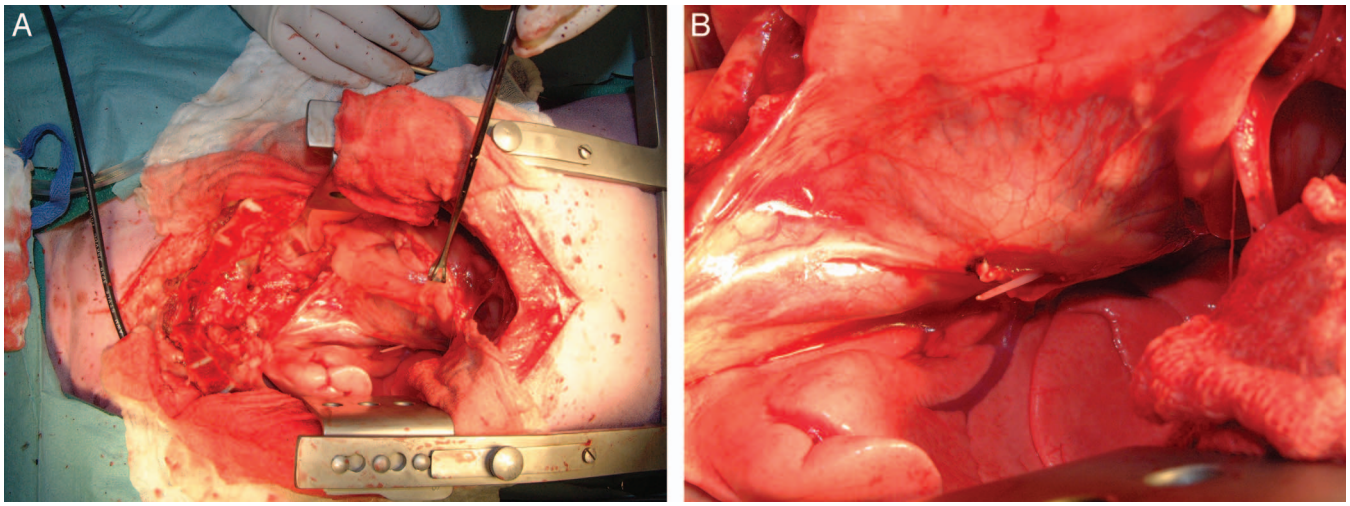

FIGURE 1 *(A) Porcupine quill seen penetrating the right ventricle near the phrenic nerve. (B) Magnified view of porcupine quill penetrating right ventricle.*

examination was the presence of multiple sutures on the ventral mandible from previous quill removal by the referring veterinarian. Hematology and serum biochemistry were performed and there were no significant abnormalities.

A computed tomography (CT) scan with 5 mm thick axial images of the thorax was obtained without contrast administration. Results of the CT revealed mild subcutaneous emphysema along the right lateral thoracic body wall from previous thoracocentesis. Severe bilateral pneumothorax resulting in atelectasis of the lung lobes was also noted. No porcupine quills were observed.

Exploratory thoracotomy was recommended in an attempt to locate the suspected migrating quill and manage the pneumothorax. A ventral midline sternotomy was performed. Bruising was noted adjacent to the thoracic inlet and right cranial lung lobe. The thoracic cavity was filled with saline to check for leakage from the lung lobes; however, no leakage was detected. A quill was identified penetrating in the right ventricle of the heart in close proximity to the right vagus nerve (**Figures 1A, B**). The pericardium was incised to provide better exposure to the quill. A 3-0 polydiaxonone purse-string suture was placed in the myocardium around the quill. The quill was then removed (**Figure 2**) while simultaneously tightening to purse-string suture to prevent hemorrhage. A 16 French gauge thoracostomy tube was inserted in the right hemithorax. The thoracic cavity was lavaged and inspected for any air leakage from the lung lobes before closure. The quill was submitted for aerobic and anaerobic culture. The median sternotomy was closed routinely. The thoracostomy tube was removed after 24 hr. No bacteria were grown on culture; however, the dog was prophylactically treated with Clavamox 12.5mg/kg *per os q* 12 hr for 6 wk due to the concern of the development of endocarditis. The dog recovered uneventfully from surgery with no reported complications. The dog died 5 yr later after being hit by a car.

FIGURE 2 *3.2cm porcupine quill after removal from right ventricle.*

Discussion

Quilling injuries most commonly involve the head and neck of the dog, followed by the limbs and the trunk.[9] When a dog is attacked by a porcupine, they are often affected in multiple locations with up to hundreds of quills penetrating their skin, as was seen in the present case.[9] As quills often breakoff at the level of the skin, their retrieval can be quite difficult, often leading to quills being left behind.[9] Due to the barbs on each quill, they have a tendency to migrate deeper into tissue rather than backing out.[9] Quills have been previously described in the orbit, globe, brain, digital flexor sheaths, spinal canal, vertebrae, joints, lungs, heart, and

pericardium.[8–12,14] Complications associated with quilling injuries are most commonly limited to cutaneous abscesses, which can be easily managed on an outpatient basis; however, reports of catastrophic ocular damage, septic arthritis, endocarditis, seizures, pneumothorax, and death have been associated with their migration.[10–12,14]

Various imaging modalities have been used to identify quill foreign bodies in veterinary literature. Ultrasound has been reported to be a useful imaging modality to identify quills in previous studies within the orbit, globe, and joints.[11,12] However, ultrasound is not the best imaging modality to evaluate changes in lung parenchyma and, hence, it was not considered in the present case. In hindsight, knowing now that the quill was penetrating the pericardium and myocardium, it may have been possible to have visualized the foreign body through an echocardiogram. MRI has been reported in the diagnosis of a quill foreign body in one dog; however, the quill was only noted retrospectively following an exploratory dorsal laminectomy.[14] Furthermore, MRI of the thoracic cavity is usually not recommended without the appropriate software because of motion artifacts caused by respiratory movements.[15]

CT scans have been used for the detection of porcupine quill foreign bodies within the brain; however, a quill was not identified on thoracic CT in the present case.[10] There are a number of possible explanations for not visualizing the quill foreign body in the case described herein, including the location of the foreign body, the width of the axial sections (2 mm sections were used in the previous case compared to 5 mm sections in the present case), the lack of contrast administration, and the experience of the radiologist. Regardless, as evidenced by this case, the absence of identification of a quill on a CT scan does not rule out its presence.

Conclusion

Cardiac foreign bodies are a rarely reported occurrence in veterinary literature. Migration of sewing needles and wooden skewers from the gastrointestinal tract, intravascular migration of catheter fragments, metallic projectiles, and a single previous case of a quill migration have previously been described.[1,3–6,8,16] Surgical intervention has been debated for small metallic projectile foreign bodies in both human and veterinary literature; however, early surgical intervention is recommended in people with acute injuries because complications, such as endocarditis, restrictive pericarditis, sepsis, and death, are reported at a rate of up to 71%.[4] In this case, the presenting complaint of bilateral pneumothorax was secondary to a migrating quill foreign body, which ultimately ended up penetrating into the right ventricular wall of the heart. The quill may have resulted in life threatening complications if it had not been surgically removed.

Several methods have been successfully used to retrieve cardiac foreign bodies in dogs, including endovascular retrieval, thoracoscopic retrieval, removal via thoracotomy, and cardiopulmonary bypass with open heart surgery.[1,3–5,8,16] In the present case, the CT exam did not reveal an intracardiac foreign body and, hence, more specific cardiac retrieval procedures were not considered. A median sternotomy is considered the gold standard for exploring the thoracic cavity in cases of spontaneous pneumothorax because of the ability to explore the left and right lung lobes.[13,17] Thoracoscopic exploration has also been described, but was not used in the present case because of surgeon preference for an open procedure.[8] Interestingly, despite the fact that the quill presumably migrated through the lung fields to cause a pneumothorax, no air leakage was identified from any of the lung lobes during surgery suggesting that the affected lung lobe(s) had sealed the perforation once the quill had migrated through the lobe(s).

Postoperatively, the patient in this case did excellently with no observed complications. In veterinary literature, postoperative complications following removal of intracardiac foreign bodies are rare.[1,3–5] The reported complications are often a result of the initial injury and disease caused by the foreign body rather than the development of disease secondary to the surgery or residual effects of the foreign body itself.[4,16]

Although the concern for the development of postoperative endocarditis or pericarditis has been expressed, it has not been reported to date in veterinary literature.[16] Conversely, patients who present with endocarditis, pericarditis, septicemia, or disseminated intravascular coagulation appear to have resolution of their clinical signs following removal of the foreign body.[4,16] This finding is consistent with human literature where patients who survive removal of a foreign body have a good prognosis if there is not extensive trauma to the heart.[18–22]

REFERENCES

1. Calvo I, Weilland L, Pratschke K. Traumatic myocardial laceration as a result of suspected cranial migration of a sewing needle from the stomach of a dog. *Aust Vet J* 2009;89:444–446.
2. Crosara S, Zabarino S, Morello E, et al. Migration of a kirschner wire to the heart in a Yorkshire terrier. *J Small Anim Pract* 2008;49:100–102.
3. Culp W, Weisse C, Berent A, et al. Percutaneous endovascular retrieval of an intravascular foreign body in five dogs, a goat, and a horse. *J Am Vet Med Assoc* 2008;232:1850–1856.
4. Elliott J, Mayhew P. Diagnostic challenges and treatment options of a suspected pericardial metallic projectile foreign body in a dog. *J Vet Emerg Crit Care (San Antonio)* 2011;21:684–691.
5. Gentile J., Bulmer B, Heaney A, et al. Endovascular retrieval of embolized jugular catheter fragments in three dogs using nitinol gooseneck snare. *J Vet Cardiol* 2008;10:81–85.

6. Hunt GB, Bellenger CR, Allan GS, et al. Suspected cranial migration of two sewing needles from the stomach of a dog. *Vet Rec* 1991;128:329–330
7. Hunt GB, Worth A, Marchevsky A. Migration of wooden skewer foreign bodies from the gastrointestinal tract in eight dogs. *J Small Anim Pract* 2004;45:362–367.
8. McCarthy, T. Porcupine quill retrieval with thoracoscopy. *Vet Med-US* 2004;99:15.
9. Johnson M, Magnusson D, Shmon CL, et al. Porcupine quill injuries in dogs: a retrospective of 296 cases (1998–2002). *Can Vet J* 2006;47:677–682
10. Sauve C, Sereda N, Sereda C. Identification of an intra-axial porcupine quill foreign body with computed tomography in a canine patient. *Can Vet J* 2012;53:187–189.
11. Brisson B, Bersenas A, Etue S. Ultrasonagraphic diagnosis of septic arthritis secondary to porcupine quill migration in a dog. *J Am Vet Med Assoc* 2004;224:1467–1470.
12. Grahn B, Szentimrey D, Pharr JW, et al. Ocular and orbital porcupine quills in the dog: a review and case series. *Can Vet J* 1995;36:488–493.
13. Lipscomb V, Brockman D. CT scanning of dogs with spontaneous pneumothorax. *Vet Rec* 2004;154:733–7.
14. Schneider A, Chen An, Tucker R. Imaging diagnosis–vertebral canal porcupine quill with presumptive secondary arachnoid diverticulum. *Vet Radiol Ultrasound* 2010;51:152–154.
15. Bogaert J, Dymarkowski S, Taylor AM, et al. *Clinical Cardiac MRI*. 2nd ed. Berlin: Springer; 2012: 16–21.
16. Sereda N, Towl S, Maisenbacher III HW, et al. Intracardiac foreign body in a dog. *J Vet Cardiol* 2009;11:53–58.
17. Reetz JA, Caceres AS, Suran JN, et al. Sensitivity, positive predictive value, and interobserver variability of computed tomography in the diagnosis of bullae associated with spontaneous pneumothorax in dogs: 19 cases (2003–2012). *J Am Vet Med Assoc* 2013;243:244–51.
18. Baker C, Nigro J, Daggett CW, et al. Needle embolism to the heart. *Ann Thorac Surg* 2004;77:1102.
19. Keogh B, Oakley C, Taylor K. Chronic constrictive pericarditis caused by self-mutilation with sewing needles. *Br Heart J* 1988;59:77–80.
20. Perrotta S, Perrotta A, Lentini S. In patients with cardiac injuries caused by sewing needles is the surgical approach the recommended treatment? *Interact Cardiovasc Thorac Surg* 2010;10:783–792.
21. Wang X, Zhao X, Du D, et al. Management of metallic foreign bodies in the heart. *J Card Surg* 2012;27:704–706.
22. Yang Li, Wang J, Wu W. Echocardiographic detection of intracardiac non-metallic foreign body complicated by infective endocarditis. *Eur Heart J* 2007;28:58.