Proximal Radial and Distal Humeral Osteosarcoma in 12 Dogs

Twelve dogs were diagnosed with osteosarcoma of the proximal radius or distal humerus from 1990 to 2002, representing 1.0% of all dogs diagnosed with appendicular osteosarcoma. The median body weight (29.8 kg) was significantly less than that of dogs with appendicular osteosarcoma at other sites. Ten dogs were treated with amputation and chemotherapy. These dogs had a metastatic rate of 60%, a median metastasis-free interval of 356 days, and a median survival time of 824 days. There were no significant differences in metastasis-free interval or survival time between dogs with osteosarcoma of the proximal radius or distal humerus and dogs with appendicular osteosarcoma at other sites. **J Am Anim Hosp Assoc 2004;40:461-467.**

Julius M. Liptak, BVSc, MVetClinStud, FACVSc

William S. Dernell, DVM, MS, Diplomate ACVS

Rodney C. Straw, BVSc, Diplomate ACVS

Scott A. Rizzo, BS, MS

Mary H. Lafferty, CVT

Stephen J. Withrow, DVM, Diplomate ACVS, Diplomate ACVIM (Oncology)

RS

From the Animal Cancer Center, College of Veterinary Medicine and Biomedical Sciences, Colorado State University, Fort Collins, Colorado 80523.

Doctor Liptak's current address is Department of Clinical Studies, Ontario Veterinary College, University of Guelph, Guelph, Ontario, N1G 2W1, Canada.

Doctor Straw's current address is Brisbane Veterinary Specialist Centre, Albany Creek, Queensland 4035, Australia.

Introduction

Osteosarcoma is the most common primary bone tumor in dogs and can involve bones in both the axial and appendicular skeleton.[1] Appendicular osteosarcoma is generally a disease of middle-aged, large-breed dogs. A bimodal age distribution is reported with a small subset of dogs presented at 18 to 24 months and a large population of dogs presented at 7 to 9 years of age.[1,2] The median weight of dogs with appendicular osteosarcoma is 40 kg, although increasing height is a more important risk factor than body weight.[2] Appendicular osteosarcoma originates in the metaphyseal region of long bones and occurs twice as frequently in the thoracic limb than the pelvic limb.[1,3,4] The distal radius (34.9%) and proximal humerus (18.4%) are the two most commonly affected sites, and there is a relatively even distribution between the distal tibia (12.5%), proximal tibia (7.2%), distal femur (7.9%), and proximal femur (4.6%).[1,3]

Appendicular osteosarcoma in the proximal radius and distal humerus is rare and accounts for <2.0% of all canine cases.[3] The purpose of the present study was to retrospectively evaluate the signalment, presentation, and outcome of dogs with osteosarcoma of the proximal radius or distal humerus and to compare these data to dogs diagnosed with appendicular osteosarcoma at other sites during the same time period.

Materials and Methods

The bone tumor database and medical records at Colorado State University Veterinary Teaching Hospital were reviewed from June 1990 to June 2002 for dogs with primary osteosarcoma of the proximal radius and distal humerus. Inclusion criteria included radiographic localization of the tumor site and histopathological confirmation of osteosarcoma. Dogs were excluded if proximal radial or distal humeral involvement resulted from either metastatic osteosarcoma or tumors other than osteosarcoma.

The records of all dogs were reviewed, and information was retrieved on signalment, presenting signs, physical examination findings, hematology

and serum biochemistry tests, regional and three-view thoracic radiography, bone survey radiography or nuclear scintigraphy, treatment, and outcome. Prior to 1995, bone survey radiographs, consisting of lateral radiographs of the limbs and ventrodorsal radiographs of the pelvis and vertebral column, were performed to screen for metastatic disease of the skeleton.[5] Whole-body bone scans, using technetium^{99m} hydroxymethylene diphosphonate (Tc^{99m} HDP), were used to screen for skeletal metastases after 1995.[6,7]

Treatments for dogs with osteosarcoma of the proximal radius and distal humerus were selected by the owners and included palliative analgesia or forequarter amputation and adjunctive chemotherapy.[1] The outcome parameters measured included local tumor recurrence, metastasis, and survival time. Metastasis-free interval was defined as the period from diagnosis of osteosarcoma to the detection of metastasis. Survival time was defined as the period from diagnosis of osteosarcoma to death. The cause of death was recorded and attributed to osteosarcoma if it was related to treatment (e.g., analgesia, surgery, or chemotherapy), local tumor recurrence, or metastasis. In dogs with metastatic disease, the sites of metastasis were recorded based on clinical (n=5) and necropsy findings (n=1). For comparison, outcomes for dogs with appendicular osteosarcoma at sites other than the proximal radius and distal humerus were matched for type of treatment (i.e., palliative analgesia or limb amputation with adjunctive chemotherapy).

Body weights were compared using Student's t-test and the median metastasis-free interval and median survival time analyzed using Kaplan-Meier survival analysis with log rank.[a] Significance was established with a P value <0.05.

Results

Case Data

From June 1990 to June 2002, 1180 dogs were diagnosed with appendicular osteosarcoma, and primary involvement of either the proximal radius or distal humerus was reported in 12 (1.0%) of these dogs. A number of different breeds were represented, including mixed-breed dogs (n=3), Labrador retriever (n=2), golden retriever (n=2), and one each of an Akita, border collie, Dalmatian, greyhound, and rottweiler . There was an even sex distribution with six male dogs (one intact, five castrated) and six female dogs (all spayed). The median age at presentation was 8.0 years (range 1.1 to 13.0 years), and the median body weight was 29.8 kg (range 16.6 to 63.0 kg).

Clinical Findings

Physical examination findings included lameness in all dogs, ranging from mild weight bearing to nonweight bearing, and a palpable mass in three dogs. Hematological results were within the normal reference ranges in all dogs. Alkaline phosphatase levels were increased in four dogs (range 257 to 1242 IU/L; reference range 18 to 160 IU/L), and two of these dogs also had increased levels of alanine transferase (143 and 183 IU/L, reference range 10 to 120 IU/L) and either γ-glutamyltransferase (11 IU/L, reference range 0 to 10 IU/L) or total bilirubin (0.7 mmol/L, reference range 0 to 0.4 mmol/L). No other serum biochemical abnormalities were noted.

Regional and thoracic radiographs were evaluated in all dogs. Limb radiographs were suggestive of a neoplastic process in all dogs. Typical radiographic features of a primary bone tumor included a monostotic lesion consisting of a mixed lytic to productive pattern with loss of cortical bone, and a pathological fracture in two dogs.[8] Subjectively, bone lysis was the predominant radiographic change in eight dogs. The proximal radius was involved in five dogs (four right-sided and one left-sided) [Figures 1A, 1B], and the distal humerus was involved in seven dogs (five left-sided and two right-sided) [Figures 2A, 2B]. In one dog, osteosarcoma originated in the distal humerus at the site of a previous fracture that was surgically repaired using an intramedullary pin and cerclage wire. Metastatic disease was not detected in the lungs or bones of any dog at the time of diagnosis using three-view thoracic radiography (n=12), bone survey radiography (n=5), or whole-body Tc^{99m} HDP scans (n=7).

Treatment

Affected dogs were treated either palliatively (n=2) or with forequarter amputation and postoperative chemotherapy (n=10). Palliative management consisted of the administration of oral analgesic drugs, such as nonsteroidal anti-inflammatory agents or opioids. In dogs treated with forequarter amputation, perioperative complications were not reported, and all dogs were able to ambulate within 24 hours of surgery. Adjunctive chemotherapy protocols included cisplatin[b] alone (four doses at 70 mg/m^2 intravenously q 3 weeks with saline diuresis; n=3), doxorubicin[c] alone (five doses at 30 mg/m^2 intravenously q 2 to 3 weeks; n=4), subcutaneous implantation of a biodegradable cisplatin-containing polymer[d] (n=1), and an alternating protocol of carboplatin[e] (300 mg/m^2) and doxorubicin (30 mg/m^2) intravenously q 3 weeks for six total treatments (n=2).[9] Two dogs did not complete their full course of chemotherapy. A fifth dose of doxorubicin was not administered in one dog (case no. 9) because of detection of pulmonary metastases, and renal failure was diagnosed in another dog (case no. 5) after two doses of cisplatin. This last dog received two doses of carboplatin and completed the chemotherapy protocol without further complications.

Follow-up and Outcome

Follow-up information was available for 10 dogs. Two dogs were lost to follow-up at 182 and 711 days postoperatively [see Table]. The two dogs treated only with analgesics were euthanized 11 and 74 days postdiagnosis because of unremitting pain. Metastatic disease was diagnosed in six (60%) of the 10 dogs treated with surgery and chemotherapy, with a median metastasis-free interval of 356 days (range 24 to 767 days). Metastatic sites included the lungs (n=2), bones (n=3), or both lungs and bones (n=1).

Table

Treatments and Outcomes of 12 Dogs With Osteosarcoma of the Proximal Radius or Distal Humerus

Case No.	Site of Tumor	Side	Treatments	Metastasis Detected	MFI* (d)	Cause of Death†	Survival Time (d)
1	Proximal radius	Left	Amputation, cisplatin	-	-	Lost to follow-up	711
2	Proximal radius	Right	Amputation, cisplatin	-	-	Lost to follow-up	182
3	Distal humerus	Left	Analgesia	-	-	Pain	11
4	Distal humerus	Left	Analgesia	-	-	Pain	74
5	Distal humerus	Left	Amputation, cisplatin-carboplatin	Lungs	243	HSA	295
6	Distal humerus	Right	Amputation, OPLA‡	Maxilla, zygomatic arch	24	CRF	120
7	Distal humerus	Left	Amputation, doxorubicin	Lungs, radius, kidney	153	Metastasis	180
8	Proximal radius	Right	Amputation, doxorubicin	Humerus	767	Metastasis	824
9	Proximal radius	Right	Amputation, doxorubicin	Lungs	71	Metastasis	80
10	Distal humerus	Right	Amputation, carboplatin-doxorubicin	-	-	SCC	402
11	Proximal radius	Right	Amputation, carboplatin-doxorubicin	-	-	Alive	686
12	Distal humerus	Left	Amputation, doxorubicin	Tibia	356	Metastasis	541

* MFI=metastasis-free interval
† HSA=hemangiosarcoma; CRF=chronic renal failure; SCC=squamous cell carcinoma
‡ OPLA=open-cell polylactic acid impregnated with cisplatin

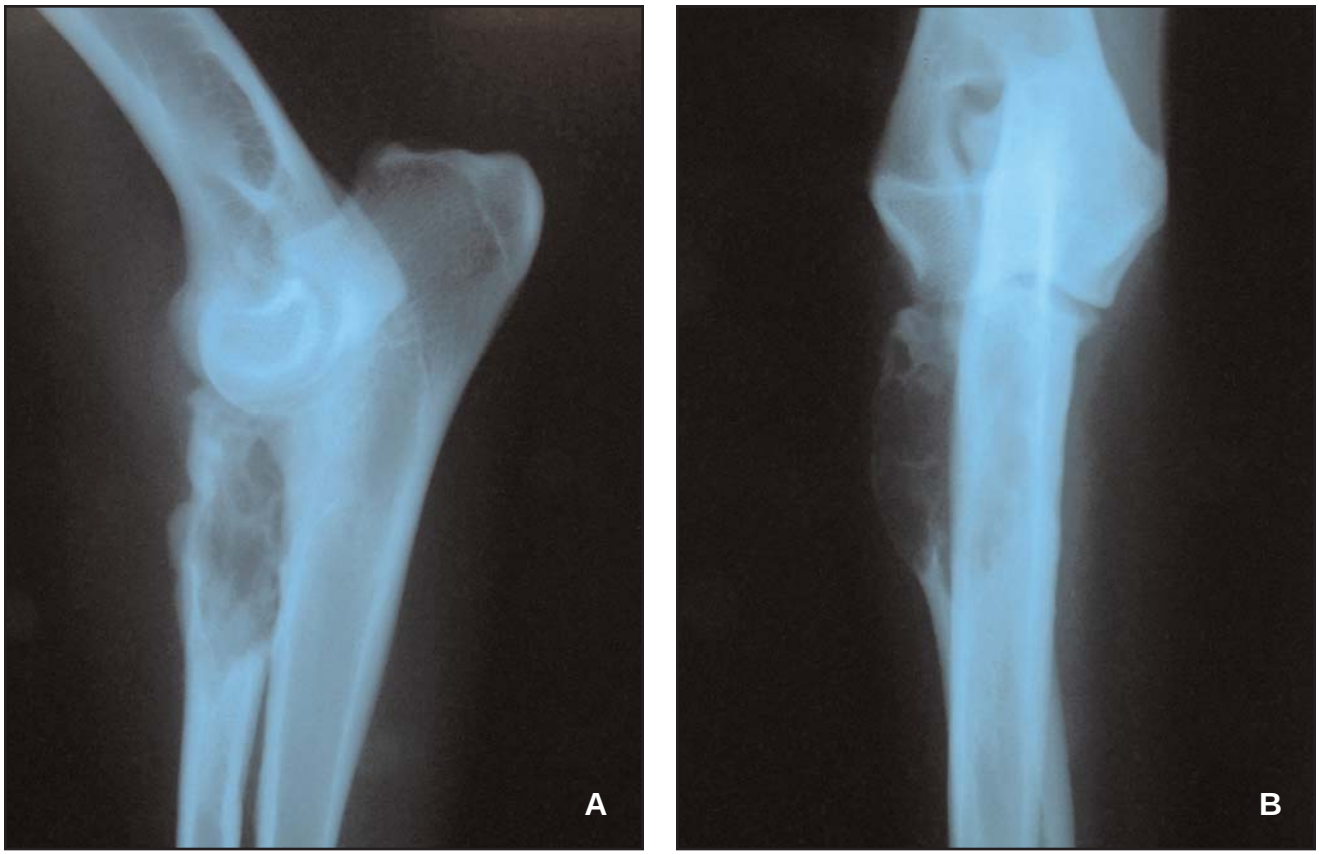

Figures 1A, 1B—Mediolateral **(A)** and dorsopalmar **(B)** radiographs of a 7-year-old golden retriever (case no. 11) with osteosarcoma of the proximal radius.

Pulmonary metastasectomy was performed in one dog (case no. 5) 243 days postamputation to treat symptomatic hypertrophic osteopathy.[10] This dog was euthanized 51 days after metastasectomy because of a metastatic splenic hemangiosarcoma. One dog (case no. 6) with metastasis to the maxilla and zygomatic arch was euthanized 120 days postoperatively as a result of chronic renal failure rather than metastatic disease.

Death was attributed to osteosarcoma in six dogs, primarily from pain in the two dogs treated palliatively and from metastatic disease in four dogs treated with amputation and chemotherapy. Two dogs were lost to follow-up, and one dog each died as a result of metastatic hemangiosarcoma, chronic renal failure, and sublingual squamous cell carcinoma. One dog (case no. 11) was alive without evidence of local recurrence or metastasis 686 days postoperatively. The median survival time was 824 days (range 11 to 824 days).

During the same time period, 1168 dogs were diagnosed with histologically confirmed osteosarcoma at other appendicular sites. Of these, sufficient information was available on 437 dogs treated with limb amputation and adjunctive chemotherapy. A further 79 were treated with analgesic drugs alone. Body weights were recorded for 501 dogs, and the median weight of these dogs was 38 kg (range 8 to 91 kg). These weights were significantly heavier than the dogs diagnosed with osteosarcoma of the proximal radius or distal humerus ($P<0.001$). In dogs treated with analgesic drugs alone, the median survival time was 98 days (range 1 to 894 days). In dogs treated with limb amputation and chemotherapy, the metastatic rate was 64.4%, with a median metastasis-free interval of 184 days (range 0 to 1068 days) and a median survival time of 327 days (range 3 to 3037 days). There were no significant differences in either the metastasis-free interval ($P=0.3261$) or survival time ($P=0.2035$) between dogs with osteosarcoma adjacent to the elbow or at other appendicular sites [Figure 3].

Discussion

Osteosarcoma of the proximal radius or distal humerus was diagnosed in 12 dogs between 1990 and 2002. These dogs represented 1.0% of all appendicular osteosarcomas diagnosed at the Animal Cancer Center at Colorado State University during this time. The rare incidence of osteosarcoma adjacent to the elbow was similar to previous reports detailing the distribution of osteosarcoma lesions in dogs.[3,4]

The signalment of dogs with osteosarcoma of the proximal radius or distal humerus was similar to that of dogs with osteosarcoma at other appendicular sites. In the present study, the median age, age range, and sex distribution were similar to other reports.[1] A major difference was noted in body weight between dogs with osteosarcoma adjacent to the elbow and dogs with tumors at other appendicular sites. The median body weight of 29.8 kg in the present study was significantly lower than the median weight of similarly

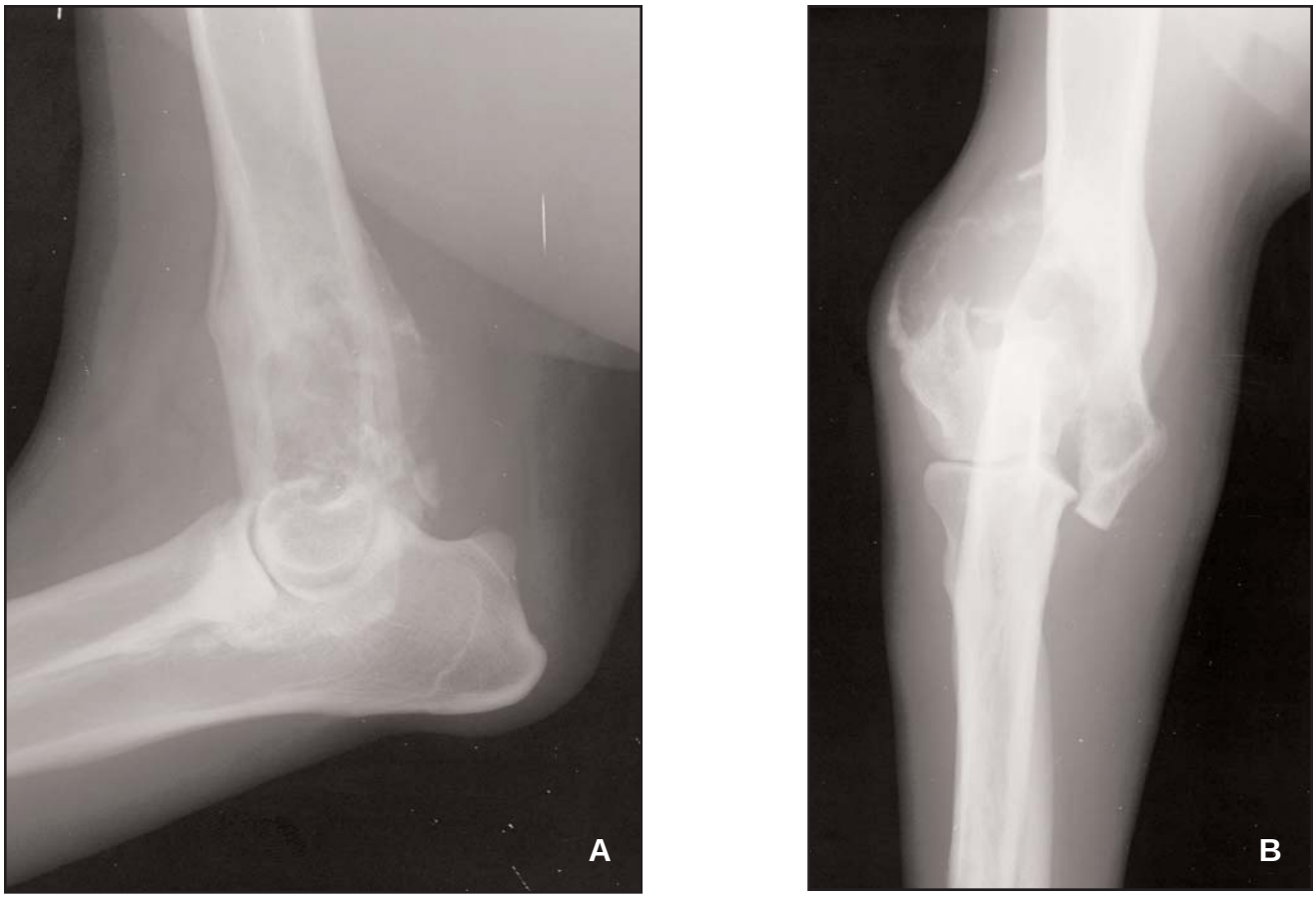

Figures 2A, 2B—Mediolateral **(A)** and dorsopalmar **(B)** radiographs of an 11-year-old border collie (case no. 10) with a pathological fracture from an osteosarcoma of the lateral humeral condyle.

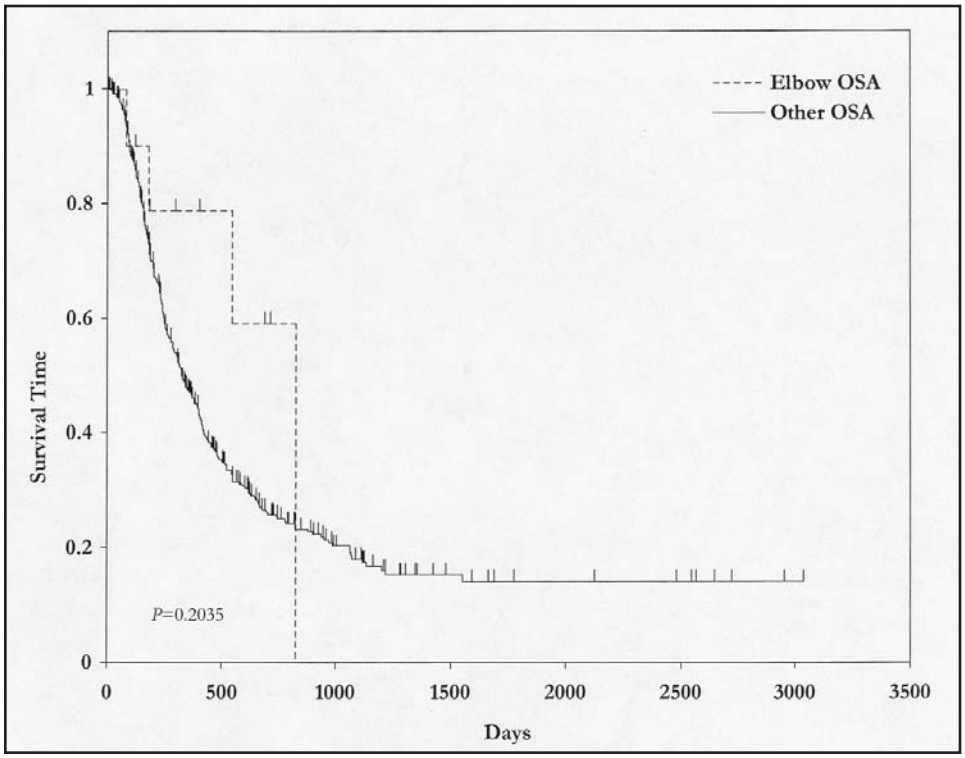

Figure 3—Kaplan-Meier survival curve for dogs with osteosarcoma of the proximal radius or distal humerus (Elbow OSA) compared to dogs with osteosarcoma in other appendicular sites (Other OSA) treated with forequarter amputation and adjunctive chemotherapy during the same time period.

treated dogs with osteosarcoma at other sites, and it was >20% lower than weights historically reported in dogs with appendicular osteosarcoma at other locations.[11,12] This weight discrepancy was difficult to explain, as primary osteosarcoma has not been reported adjacent to the elbow in small-breed dogs, and despite the lower body weight, the affected breeds were still considered to be large-breed dogs.[13] Large body weight is a recognized risk factor in the development of appendicular osteosarcoma in dogs.[2]

Stage IIB osteosarcoma was diagnosed in all dogs in the present study. A previous history of trauma and fracture repair was noted in one dog (case no. 6). However, the incidence of osteosarcoma adjacent to the elbow did not appear to be affected by prior fractures, as most post-fracture sarcomas are diaphyseal and occur in the pelvic limb, particularly the femur.[14]

Treatments and outcomes in the dogs reported here were similar to other studies and were not substantially different from dogs with appendicular osteosarcoma of other sites treated similarly during the same time period. The median survival time for dogs with osteosarcoma treated with analgesia alone has not been reported, but it is significantly shorter than the median survival time of 103 to 175 days for dogs treated with amputation alone.[15-20] The survival times of 11 and 74 days for dogs treated only with analgesics in this study were in accordance with these prior findings.

In dogs with appendicular osteosarcoma, treatment aimed at curing their cancer involves surgical ablation of the primary tumor and postoperative chemotherapy.[1] Limb amputation was performed for resection of the primary tumor in this study, although limb salvage of a proximal radial osteosarcoma has been reported.[21] Limb-sparing surgery was offered in some cases but was not pursued because of an inability to salvage the decubital joint and expected poor limb function following arthrodesis of the elbow.[22]

Chemotherapeutic protocols for osteosarcoma have not been compared in objective studies, although there appears to be minimal survival differences between single- and multiple-agent protocols using cisplatin, carboplatin, or doxorubicin.[11,12,15-20,23-25] The metastatic rate and sites of metastasis detected in the present study were similar to other reports, with metastases to lung and bone reported in 60% of dogs at a median of 356 days postoperatively. This metastatic rate was lower than the 80% to 90% commonly cited for dogs with appendicular osteosarcoma, but it was similar to the 64.4% metastatic rate found in dogs with osteosarcoma at other appendicular sites during the same time period.[1] The median survival time for the dogs in the study reported here was 824 days. This time was not significantly different from the median survival time for dogs with appendicular osteosarcoma at other sites, but was numerically superior to historical reports of 235 to 366 days.[11,12,15-20,23-25] This prolonged survival time should not be misinterpreted, because the median survival time may have been increased by the small sample size and the degree of censoring.

Conclusion

Osteosarcoma of the proximal radius and distal humerus was diagnosed rarely in this study. Body weight in affected dogs was significantly lower than the weight of dogs with appendicular osteosarcoma at other sites, although affected dogs were still considered to be large-breed dogs. Osteosarcoma adjacent to the elbow differed minimally in its clinical presentation and course from osteosarcoma at other appendicular sites, and it had a similar prognosis following palliative treatment or treatment designed to achieve a potential cure.

---

[a] SPSS 11.0.1, SPSS Inc., Chicago, IL 60606-6307
[b] Platinol; Bristol-Myers Squibb Oncology, Princeton, NJ 08543
[c] Doxorubicin HCl injection; Bedford Laboratories, Bedford, OH 44146
[d] OPLA; Kensey Nash Corporation, Exton, PA 19341
[e] Paraplatin; Bristol-Myers Squibb Oncology, Princeton, NJ 08543

References

1. Dernell WS, Straw RC, Withrow SJ. Tumors of the skeletal system. In: Withrow SJ, MacEwen EG, eds. Small Animal Clinical Oncology. Philadelphia: WB Saunders, 2001:378-417.
2. Ru G, Terracini B, Glickman LT. Host related factors for canine osteosarcoma. Vet J 1998;156:31-39.
3. Brodey RS, Riser WH. Canine osteosarcoma: a clinicopathological study of 194 cases. Clin Orthop 1969;62:54-64.
4. Knecht CD, Priester WA. Musculoskeletal tumors in dogs. J Am Vet Med Assoc 1978;172:72-74.
5. LaRue SM, Withrow SJ, Wrigley RH. Radiographic bone surveys in the evaluation of primary bone tumors in dogs. J Am Vet Med Assoc 1986;188:514-516.
6. Forrest LJ, Thrall DE. Bone scintigraphy for metastasis detection in canine osteosarcoma. Vet Radiol Ultrasound 1994;35:124-130.
7. Jankowski MK, Steyn PF, Lana SE, *et al*. Clinical sensitivity and specificity of nuclear scanning with 99mTc-HDP for osseous metastasis in dogs with osteosarcoma. Proc Vet Cancer Society 2001;21:35.
8. Wrigley RH. Malignant versus nonmalignant bone disease. Vet Clin North Am Small Anim Pract 2000;30:315-347.
9. Withrow SJ, Straw RC, Brekke JH, *et al*. Slow release adjuvant cisplatin for treatment of metastatic canine osteosarcoma. Eur J Exp Musculoskel Res 1995;4:105-110.
10. Liptak JM, Monnet E, Dernell WS, *et al*. Pulmonary metastatectomy in the management of four dogs with hypertrophic osteopathy. Vet Comp Oncol 2004;2:1-12.
11. Bergman PJ, MacEwen EG, Kurzman ID, *et al*. Amputation and carboplatin for treatment of dogs with osteosarcoma: 48 cases (1991 to 1993). J Vet Intern Med 1996;10:76-81.
12. Bailey D, Erb H, Williams L, *et al*. Carboplatin and doxorubicin combination chemotherapy for the treatment of appendicular osteosarcoma in the dog. J Vet Intern Med 2003;17:199-205.
13. Cooley DM, Waters DJ. Skeletal neoplasms of small dogs: a retrospective study and literature review. J Am Anim Hosp Assoc 1997;33:11-23.
14. Knecht CD, Priester WA. Osteosarcoma in dogs: a study of previous trauma, fracture, and fracture fixation. J Am Anim Hosp Assoc 1978;14:82-84.
15. Mauldin GN, Matus RE, Withrow SJ, *et al*. Canine osteosarcoma: treatment by amputation versus amputation and adjuvant chemotherapy using doxorubicin and cisplatin. J Vet Intern Med 1988;2:177-180.
16. Shapiro W, Fossum TW, Kitchell BE, *et al*. Use of cisplatin for treatment of appendicular osteosarcoma in dogs. J Am Vet Med Assoc 1988;192:507-511.

17. Straw RC, Withrow SJ, Richter SL, *et al*. Amputation and cisplatin for treatment of canine osteosarcoma. J Vet Intern Med 1991;5:205-210.
18. Spodnick GJ, Berg J, Rand WM, *et al*. Prognosis for dogs with appendicular osteosarcoma treated by amputation alone: 162 cases (1978-1988). J Am Vet Med Assoc 1992;200:995-999.
19. Thompson JP, Fugent MJ. Evaluation of survival times after limb amputation, with and without subsequent administration of cisplatin, for treatment of appendicular osteosarcoma in dogs: 30 cases (1979-1990). J Am Vet Med Assoc 1992;200:531-533.
20. Kirpensteijn J, Kik M, Rutteman GR, *et al*. Prognostic significance of a new histologic grading system for canine osteosarcoma. Vet Pathol 2002;39:240-246.
21. Morello E, Buracco P, Martano M, *et al*. Bone allografts and adjuvant cisplatin for the treatment of canine appendicular osteosarcoma in 18 dogs. J Small Anim Pract 2001;42:61-66.
22. de Haan JJ, Roe SC, Lewis DD, *et al*. Elbow arthrodesis in 12 dogs. Vet Comp Orthop Traumatol 1996;9:115-118.
23. Chun R, Garrett LD, Henry C, *et al*. Cisplatin and doxorubicin combination for the treatment of canine osteosarcoma. Proc Vet Cancer Society 2001;21:7.
24. Berg J, Weinstein MJ, Schelling SH, *et al*. Treatment of dogs with osteosarcoma by administration of cisplatin after amputation or limb-sparing surgery: 22 cases (1987-1990). J Am Vet Med Assoc 1992;200:2005-2008.
25. Berg J, Weinstein MJ, Springfield DS, *et al*. Results of surgery and doxorubicin chemotherapy in dogs with osteosarcoma. J Am Vet Med Assoc 1995;206:1555-1560.