

Oncologic Outcome after Curative-Intent Treatment in 39 Dogs with Primary Chest Wall Tumors (1992–2005)

JULIUS M. LIPTAK, BVSc, MVetClinStud, FRCVSc, Diplomate ACVS & ECVS, DEBRA A. KAMSTOCK, DVM, PhD, Diplomate ACVP, WILLIAM S. DERNELL, DVM, MS, Diplomate ACVS, GABRIELLE J. MONTEITH, BSc, SCOTT A. RIZZO, BS, MS, DVM, and STEPHEN J. WITHROW, DVM, Diplomate ACVS & ACVIM (Oncology)

Objective—To describe the clinical features and determine oncologic outcome and prognostic factors for dogs with primary tumors of the osseous chest wall.

Study Design—Historical cohort.

Animals—Dogs (n = 39) with spontaneous tumors involving the chest wall.

Methods—Medical records were reviewed for dogs with rib and/or sternal tumors treated by chest wall resection and reconstruction. Signalment, preoperative clinical features, reconstruction technique, and oncologic outcome (local tumor recurrence, metastasis, and survival time) were determined from medical records and by telephone contact with owners and referring veterinarians. Oncologic outcome and prognostic factors were determined using Kaplan–Meier survival analysis and Cox proportional hazards. Logistic regression was used to determine if increased serum alkaline phosphatase (ALP) concentration was associated with tumor type.

Results—Of the 39 dogs with tumors arising from the chest wall, 25 had osteosarcoma, 12 had chondrosarcoma, and 2 dogs had hemangiosarcoma. Median survival time (MST) for dogs with rib osteosarcoma was 290 days. Increased activity of total ALP significantly decreased survival in dogs with osteosarcoma (210 days versus 675 days, $P = .0035$). MST for dogs with rib chondrosarcoma was not reached (mean 1301 days) and survival was significantly greater than all other types of rib tumors ($P = .0321$).

Conclusion—Rib tumors should be resected with wide margins to decrease the risk of incomplete excision, because local tumor recurrence has a significant impact on the survival time. The prognosis for dogs with rib chondrosarcoma is very good, but guarded for other types of tumors.

Clinical Relevance—Osteosarcoma and chondrosarcoma are the most common primary tumors of the chest wall. Prognosis for dogs with primary rib chondrosarcoma is very good with surgery alone, but surgery and adjunctive chemotherapy is recommended for dogs with primary rib osteosarcoma and the prognosis remains guarded.

© Copyright 2008 by The American College of Veterinary Surgeons

INTRODUCTION

CHEST WALL tumors include primary tumors of the ribs and sternum, invasion of adjacent tumors into the chest wall, and metastasis from distant tumors. Primary rib tumors are the most common tumors of the chest wall and

are frequently malignant sarcomas.^{1–6} Osteosarcoma (OSA) is the most common primary rib tumor, accounting for 28–63% of the cases.^{3–6} Chondrosarcoma (CSA) is the 2nd most common primary rib tumor, accounting for 28–35% of the cases.^{3–6} Other primary bone tumors, such as fibrosarcoma and hemangiosarcoma (HSA), are uncommon.^{3–6}

From the Animal Cancer Center and Department of Microbiology, Immunology, and Pathology, College of Veterinary Medicine and Biomedical Sciences, Colorado State University, Fort Collins, CO; and Department of Clinical Studies, Ontario Veterinary College, University of Guelph, Guelph, ON, Canada.

Address reprint requests to Julius M. Liptak, BVSc, MVetClinStud, Alta Vista Animal Hospital, 2616 Bank Street, Ottawa, ON, Canada K1T 1M9. E-mail: juliusliptak@mac.com.

Submitted March 2008; Accepted April 2008

© Copyright 2008 by The American College of Veterinary Surgeons

0161-3499/08

doi:10.1111/j.1532-950X.2008.00415.x

Chest wall resection and reconstruction is recommended for the management of rib tumors in dogs. Surgical resection with ≥ 3 cm margins of normal tissue is recommended for the management of primary rib sarcomas because of their aggressive local behavior.³⁻⁶ The primary aim of the surgery is complete surgical excision, because incomplete excision significantly increases the risk of local tumor recurrence and decreases median survival times (MSTs).⁵ For dogs with primary rib OSA, surgery should be combined with adjunctive chemotherapy, because survival times are significantly increased compared with surgery alone.⁵ With appropriate curative-intent treatment, the prognosis is excellent for dogs with primary rib CSA, but guarded for other tumor types.³⁻⁶

There are a number of reports of the clinicopathologic features of primary rib tumors in dogs,¹⁻⁶ and Pirkey-Ehrhart et al⁵ investigated prognostic factors in dogs with primary rib sarcomas, especially the effect of adjunctive chemotherapy. However, since this report⁵ other prognostic factors have been identified in dogs with primary bone tumors, which have not been investigated in dogs with rib tumors, such as increased alkaline phosphatase (ALP) activity in dogs with appendicular OSA and histologic grade in dogs with OSA and CSA.⁷⁻¹¹ We report the clinical features, determine oncologic outcome, and investigate prognostic factors in dogs with primary tumors of the osseous chest wall, especially ALP activity, histologic subtype, and histologic grade.

MATERIALS AND METHODS

Inclusion Criteria

Medical records (January 1992–December 2005) at Colorado State University Veterinary Teaching Hospital and Ontario Veterinary College were reviewed for dogs with rib and/or sternal tumors treated by chest wall resection and reconstruction. Dogs were excluded if chest wall resection was performed for metastatic rib tumors or to achieve deep margins for invasive cutaneous or subcutaneous soft tissue sarcomas.

Retrieved information included signalment, physical examination findings, total serum ALP, and abnormal blood test results, thoracic imaging (radiographs, computed tomography [CT], magnetic resonance imaging [MRI], and ultrasound) findings, surgical findings, chest wall reconstruction technique, histopathologic diagnosis, postoperative treatment (chemotherapy and radiation therapy), and oncologic outcome (local tumor recurrence, metastasis, disease-free interval [DFI], and survival time [ST]). Imaging findings included location of the tumor (left or right side, and rib number) and radiographic appearance of the tumor (lytic, blastic, or mixed lytic–blastic pattern). Surgical findings included number of ribs and/or sternbrae resected, tumor invasion into adjacent organs

(i.e., pericardium or lungs), metastatic disease, and chest wall reconstruction technique.

Tumor Characteristics

Histologic samples were reviewed by a board-certified pathologist (D.A.K.). OSAs were classified according to histologic subtype (osteoblastic, chondroblastic, fibroblastic, telangiectic, and undifferentiated) and grade.^{9,10} CSAs were also histologically graded.¹¹ Surgical margins were assessed for completeness of excision.

Outcome

Oncologic outcome was determined from the medical records and telephone interview with the referring veterinarian and owner. DFI was defined as the time from surgery to detection of either local tumor recurrence or distant metastasis. ST was defined as the time from surgery to either death or study end. Cause of death was recorded as either related or unrelated to the chest wall tumor.

Data Analysis

Dogs were censored from analysis if death was unrelated to the chest wall tumor. Actuarial Kaplan–Meier survival analysis with log rank was used to test for significant differences between survival curves for tumor types. Univariate and multivariate Cox proportional hazards model was used to test which factors (signalment, total ALP, imaging findings, tumor location, tumor type, histologic subtype, histologic grade, and local tumor recurrence) were significant risk factors for tumor-related death. A P -value $< .05$ was considered significant. Significant univariate factors were fitted into a multivariate model. Other factors were added to the model, and those that were not significant at a P -value $> .50$ were removed.

RESULTS

Signalment (Table 1)

Rib resection and chest wall reconstruction was performed in 39 dogs (January 1992–December 2005) with primary chest wall tumors. Breeds were 10 each of Golden Retrievers and mix breed dogs; 5 Labrador Retrievers; 2 each of Bassett Hounds and Dobermans; and 1 each of an Australian Shepherd, British Bulldog, German Short-Haired Pointer, Rough-Coated Collie, Irish Setter, Giant Pyrennes, Rottweiler, Giant Schnauzer, Shar Pei, and Springer Spaniel. Reasons for admission included palpable chest wall mass (24 dogs), respiratory signs (4), thoracic limb lameness (2), palpable mass and lameness (5) or respiratory signs (3), and nonspecific signs (1).

Table 1. Summary Data for Dogs with Chest Wall Tumors

Factor	OSA	CSA	HSA	Total
Number	25	12	2	39
Sex				
Male	12	5	2	21
Female	13	7	0	18
Age (years)				
Median	9.0	5.5	9.5	8.0
Mean	7.8	6.0	9.5	7.3
Range	1–12	2–10	9–10	1–12
Weight (kg)				
Median	32.7	29.3	31.1	32.3
Mean	33.3	31.4	31.1	32.8
Range	9.6–54.0	9.6–45.0	21.1–41.0	9.6–54.0
ALP increased	11 (44%)	6 (50%)	2 (100%)	19 (49%)
Imaging changes				
Blastic	7	4	0	11
Lytic	10	5	1	16
Mixed	5	3	0	8
Other	3	0	1	4

OSA, osteosarcoma; CSA, chondrosarcoma; HSA, hemangiosarcoma.

Diagnostic Tests

Dogs were staged using hematology, serum biochemical profile, and thoracic radiographs. Other staging tests included whole-body scintigraphic bone scans (11); thoracic ultrasonography (4), CT (3), or MRI (1); and abdominal radiographs (2). Hematologic abnormalities included anemia (5), leukocytosis (3), mature neutrophilia (5) or neutrophilia with left shift (1), and lymphopenia (1). ALP was increased in 19 dogs (range, 179–1898 IU/L; reference interval, 20–142 IU/L). Other biochemical abnormalities included increased serum concentrations of alanine transferase (3), aspartate transferase (3), gamma-glutamyltransferase (1), and creatine kinase (6).

Tumor Location

Tumor location and radiographic pattern were determined by thoracic imaging techniques. Thirty-nine tumors originated from either the ribs (37) or sternum (2). Tumors were either lytic (16), blastic (11), mixed lytic–blastic (8), multilobular (1), periosteal (1), and no radiographic changes in 2 dogs. Tumors involved the left chest wall (20), right chest wall (17), and sternum (2). Multiple ribs were involved in 2 dogs (7th–9th ribs [1] and 9th–11th ribs [1]). Sternal tumors originated from either the 2nd sternbra (1) or 2nd and 3rd sternbrae (1). Pulmonary metastasis was suspected in 1 dog, but none of the 12 dogs staged with whole-body bone scans had evidence of secondary bone lesions.

Chest Wall Resection and Reconstruction

Rib tumors were excised with a minimum of 1 rib cranial and caudal to the tumor and ≤ 3 cm dorsal and

ventral to the tumor. Sternal tumors were excised with a minimum of 1 sternbra cranial and caudal to the tumor and 3 cm lateral to the sternal mass. Median number of ribs excised with the chest wall tumor was 3 (mean, 3.6 ribs; range, 2–6 ribs). A median of 3 ribs was resected in dogs with rib tumors (mean, 3.5 ribs; range, 2–6 ribs), and 5 ribs and sternbrae in dogs with sternal tumors (mean, 5.0 ribs and sternbrae; range, 4–6 ribs and sternbrae). The 1st rib was included in the chest wall resection in 5 dogs. Contiguous tissue was excised en bloc with the chest wall tumor, including lung lobe (10), pericardium (3), diaphragm (2), and sternum (2).

The chest wall defect was reconstructed using autogenous techniques (25 dogs), prosthetic mesh (3), and composite techniques (11). Choice of reconstruction technique was based on surgeon preference and, to a lesser extent, location and size of the defect. Further information regarding chest wall reconstruction techniques, postoperative management, and surgical and postoperative complications in this historical cohort of dogs is reported elsewhere.¹²

Osteosarcoma (Table 1)

Primary neoplasia was diagnosed in 39 dogs treated with chest wall resection and reconstruction. Tumor types included OSA (25), CSA (12), and HSA (2). Three dogs excluded from analysis had chest wall resection and reconstruction for metastatic squamous cell carcinoma and secondary invasion from a cranial mediastinal thymoma and subcutaneous leiomyosarcoma. Twenty-five dogs were considered to have primary rib OSA, but 1 dog did not have evidence of bony changes. One dog was suspected to have lung metastasis based on preoperative thoracic radiographs.

Histologic subtypes included osteoblastic (20), chondroblastic (4), and undifferentiated (1) OSA. Three dogs were diagnosed with grade I OSA, 18 dogs with grade II OSA, and 2 dogs with grade III OSA. Tumor grade was not recorded in 2 dogs, because tissue sections were not available for review. Histologic evaluation of surgical margins revealed that OSAs were completely resected in 16 dogs and incompletely excised in 5 dogs; surgical margins were not recorded in 4 dogs.

Nineteen of 23 dogs that survived the perioperative period were administered chemotherapy. One dog did not have chemotherapy, because the original diagnosis was a grade II rib fibrosarcoma; however, this tumor was later diagnosed as osteoblastic OSA during review for this study. Owners of 3 dogs declined chemotherapy. Chemotherapy protocols for the 19 dogs included carboplatin at 300 mg/m² intravenously (IV) every 3 weeks for a total 4 (2) or 6 doses (2); cisplatin at 70 mg/m² IV every 3 weeks for a total of 3 doses (1); 1 dose of carboplatin at

300 mg/m² IV, followed 3 weeks later by 1 dose of cisplatin at 70 mg/m² IV, followed by subcutaneous implantation of biodegradable open-cell polylactic acid containing 8% cisplatin (OPLA-Pt, Kensey Nash Corporation, Exton, PA) in 1 dog; OPLA-Pt alone in 1 dog; cisplatin at 70 mg/m² IV every 3 weeks for 6 doses, followed by doxorubicin at 30 mg/m² IV every 3 weeks for 2 doses (1); doxorubicin at 30 mg/m² IV every 3 weeks for a total of 4 (2) or 5 doses (7); and the chemotherapy drug and protocol was not recorded in 2 dogs.

Local recurrence occurred in 3 dogs (12.0%) at 58, 63, and 95 days postoperatively (Table 2); surgical margins were incomplete, apparently complete, and not recorded in 1 dog each. One of these dogs was diagnosed with concurrent local recurrence and metastasis, and another of these dogs was diagnosed with pulmonary metastasis 212 days after detection of local recurrence.

Metastasis was diagnosed in 15 dogs (75%) including 9 dogs with pulmonary metastasis, 3 dogs with bone metastasis (vertebra [2] and humerus [1]), 1 dog with metastasis to both the lungs and bone (rib and vertebra), 1 dog with metastasis to both the lungs and kidneys, and 1 dog with metastasis to both the skin and brain. Of these 15 dogs, 13 were administered chemotherapy. One dog with lung metastasis at diagnosis was administered postoperative chemotherapy (3 doses of cisplatin) before detection of further pulmonary metastases 196 days after surgery. One dog with pulmonary metastasis was administered an investigational gene therapy protocol that resulted in resolution of the metastatic lesion, and this dog was alive and disease-free at study end (2177 days).

Estimated MST for dogs with OSA was 290 days (confidence interval [CI] 210–815 days; estimated

mean \pm SD was 442 \pm 65 days; range, 0–2177 days). There was no significant difference in survival curves between dogs with osteoblastic and chondroblastic OSA, or between different histologic grades. Fifteen dogs died of tumor-related causes (local recurrence [1], local recurrence and metastasis [1], and metastasis [13]), 8 dogs died of unrelated causes (hemothorax [1], cardiac arrest [1] and congestive heart failure [1], surgical infection [1], splenic HSA [1], multicentric lymphosarcoma [1], and unknown [2]), 1 dog was lost to follow-up, and 1 dog was alive and disease-free 2177 days postoperatively.

Chondrosarcoma (Table 1)

Twelve dogs were diagnosed with CSA. There was no significant difference in distribution of blastic, lytic, and mixed blastic-lytic lesions between dogs with primary rib OSA and CSA.

CSAs were histologically graded as I in 7 dogs, II in 3 dogs, III in 1 dog, and tumor grade was not recorded in 1 dog. Surgical margins were histologically assessed in 11 dogs, with 10 tumors completely excised and 1 incompletely resected. One dog was administered carboplatin (300 mg/m² IV every 3 weeks for a total of 4 doses).

Local recurrence was diagnosed in 2 dogs (16.7%), 41 and 428 days postoperatively, 1 with an incompletely excised tumor and another with apparently complete resection (Table 2). Two dogs were diagnosed with metastasis to the lungs (16.7%) 212 and 419 days postoperatively. Distant metastasis was recorded in 1 dog with a grade I lesion and 1 dog with a grade II lesion. Eight dogs did not have any evidence of either recurrence or metastasis after surgical excision (67.7%).

Estimated MST for dogs with CSA was not reached and was > 3820 days (estimated mean, 1301 days; range, 67–3820 days). There were no significant differences in the survival curves between different histologic grades. Four dogs died because of disease-related reasons (local recurrence [2] and metastasis [2]), 7 dogs died of unrelated causes (cardiac arrest [1] and congestive heart failure [1], arthritis [1], prostatic carcinoma [1], metastatic grade III cutaneous STS [1], and unknown [2]), and 1 dog was alive and disease-free 2093 days postoperatively.

Hemangiosarcoma (Table 1)

HSA was diagnosed in 2 dogs. One dog was euthanatized 5 days postoperatively because of unresponsive pleural effusion. The other dog was administered postoperative carboplatin (300 mg/m² IV every 3 weeks for a total of 4 doses). This dog was diagnosed with local recurrence and lung metastasis 218 days postoperatively and was euthanatized 38 days later.

Table 2. Oncologic Outcome in Dogs with Primary Chest Wall Osteosarcoma and Chondrosarcoma

Outcome	OSA	CSA
Local recurrence	3 (12%)	2 (17%)
Median DFI	149 days	315.5 days
Metastasis	15 (75%)	2 (17%)
Median survival time		
Grade I	241 days	> 2723 days
Grade II	481 days	853 days
Grade III	226 days	> 3820 days
Median survival time		
Osteoblastic	310 days	—
Chondroblastic	> 2177 days	—
Undifferentiated	—	—
Median survival time	290 days	> 3820 days
Survival rates		
6 months	68%	91%
12 months	32%	75%
24 months	—	50%

DFI, disease-free interval; OSA, osteosarcoma; CSA, chondrosarcoma.

Prognostic Factors

Local tumor recurrence was associated with body weight (Tables 3 and 4). As the body weight increased, there was a significantly decreased risk of local tumor recurrence, although on multivariate analysis, the risk of death increased as the body weight increased. Local tumor recurrence was not significantly associated with incomplete tumor excision; however, local recurrence was 6.66 times more likely after incomplete excision.

Factors that influenced overall survival time included increased total ALP, tumor type, local tumor recurrence, and distant metastasis (Tables 3 and 4). For all tumor types, and OSA specifically, ALP increased the risk of tumor-related death. Risk of tumor-related death was 7.87 times greater for dogs with OSA and increased total ALP (Fig 1). Increased ALP did not increase the probability of death for dogs with CSA. Increased ALP activity was not predictive of tumor type, as total ALP was increased in 44% of dogs with OSA and 50% of dogs with CSA.

Estimated MST for dogs with OSA was 290 days and >3820 days for dogs with CSA. There was not a significant difference in survival curves for dogs with CSA and OSA, but dogs with rib CSA were three times less likely to die compared with dogs with OSA. Prognosis for dogs with CSA was significantly better when compared with all other tumor types (Fig 2). Overall, estimated MST was 162 days for dogs with local recurrence (CI 68–275 days), 290 days for metastasis (CI 200–481 days), and not reached and >3820 days (mean, 231.5 days) for dogs without either local recurrence or distant metastasis (Fig 3). Local recurrence was 28 times more likely and distant metastasis was 12.4 times more likely in dogs that died or were euthanatized for tumor-related reasons.

Table 3. Univariate Cox Proportional Hazard Analysis of Prognostic Factors in Dogs with Primary Chest Wall Tumors

Parameter	P-value	Hazard Ratio	95% CI
Weight	.0261*	0.918	0.847–0.994
Incomplete excision	.0712	0.150	0.023–0.992
Increased ALP			
Total	.0387*	2.420	1.047–5.601
OSA	.0035*	7.870	1.900–31.23
CSA	.8218	0.797	0.110–5.760
Tumor type			
CSA versus others	.0321*	0.304	0.102–0.903
CSA versus OSA	.0521	0.332	0.109–1.010
Local recurrence	<.0001*	28.04	5.453–144.2
Metastasis	.0009*	12.41	2.792–55.20

*Significant finding.

CI, confidence interval; ALP, alkaline phosphatase; OSA, osteosarcoma; CSA, chondrosarcoma.

Table 4. Multivariate Cox Proportional Hazard Analysis of Prognostic Factors in Dogs with Primary Chest Wall Tumors

Parameter	P-value	Hazard Ratio	95% CI
Age	.1177	1.259	0.944–1.679
Weight	.0260*	1.140	1.016–1.279
Increased ALP	.1457	0.288	0.054–1.540
Radiographic pattern			
Lytic versus mixed	.5707	–	–
Blastic versus mixed	.9437	–	–
Incomplete excision	.0741	0.064	0.003–1.307
Chemotherapy**	.4689	2.675	0.187–38.34
Tumor type			
OSA versus others	.1091	0.420	0.001–2.033
CSA versus others	.0177*	0.0088	0.000–0.429
CSA versus OSA	.2798	–	–
Local recurrence	.0003*	901.08	23.02–35265.6
Metastasis	.0112*	83.865	2.738–2568.5

*Significant finding.

**Chemotherapy for dogs with osteosarcoma.

CI, confidence interval; ALP, alkaline phosphatase; OSA, osteosarcoma; CSA, chondrosarcoma.

DISCUSSION

Rib Tumor Features and Outcome

Clinical features and outcome for dogs with rib tumors was consistent with other reports.^{1–6} The 2 most common rib tumors were primary OSA and CSA.^{3–6} Signalment was typically older, large breed dogs with no breed or sex predilection.^{2–6} Age is an inconsistent finding in dogs with rib tumors, with dogs reported to be either young (median, 2.0–4.5 years)^{2,4,5} or old (median, 7.0–9.0 years)^{3–6} on admission.

Clinical signs were similar to those in other reports, including visible or palpable chest wall mass, thoracic limb lameness, and altered breathing pattern.^{2–6} Thoracic limb lameness can be caused by mechanical interference or muscular or brachial plexus invasion from primary rib tumors arising from the 1st to 4th ribs.⁶ Causes for altered breathing include decreased lung volume and expansion because of the intrapleural extent of the chest wall tumor or pleural effusion.^{1,2,4,12}

Radiographically, rib tumors were subjectively defined as primarily lytic, blastic, or mixed. There were no significant differences in radiographic patterns between different tumor types; hence, radiographic changes cannot be used to determine tumor type.² Rib tumors were evenly distributed from ribs 2 to 8, and there was no predilection for the left or right chest wall. Others have reported that ribs 4–9^{2,3,5,6} or 9–13¹³ and either the left or right chest wall were more commonly affected.^{2,3} Although we did not investigate the location of tumors along the rib, most rib tumors arise from or near to the costochondral junction.^{2,4,6} Advanced imaging was

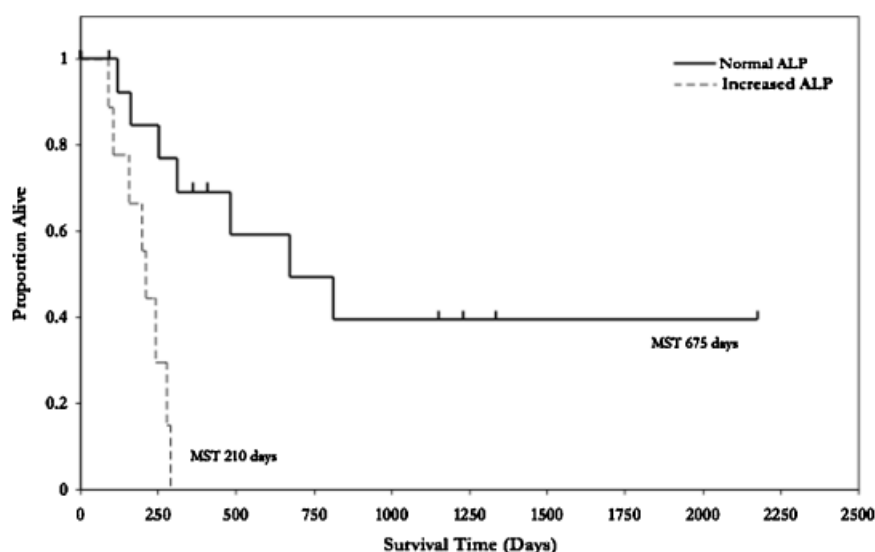


Fig 1. Kaplan–Meier survival curve for dogs with primary rib osteosarcoma and normal and increased total alkaline phosphatase (ALP). Dogs with increased ALP activity had a significantly worse estimated median survival time (210 days) compared with dogs with ALP within the normal reference interval (675 days, $P = .0035$). Tumor-related death was 7.9 times greater in dogs with rib osteosarcoma and increased ALP activity. MST, median survival time.

infrequently performed in our dogs; however, CT scans are recommended for both local and distant staging of chest wall tumors.¹⁴ Local staging assists in surgical planning by determining tumor size and location, extent of rib involvement (both number of ribs and dorsal and ventral extent), and whether there is adhesion or invasion into adjacent structures (lungs, pericardium, sternum, vertebra).¹⁴ Detection of metastatic pulmonary lesions is

also significantly more sensitive using helical CT scans compared with survey radiographs, and this may be more pertinent in dogs with rib tumors because of superimposition of the lungs by the chest wall mass and pleural effusion.^{14,15} There was a relatively high incidence of bone metastasis in dogs with primary rib OSA (16%) and, similar to appendicular OSA in dogs,¹⁶ whole-body bone scans are recommended for detection of occult syn-

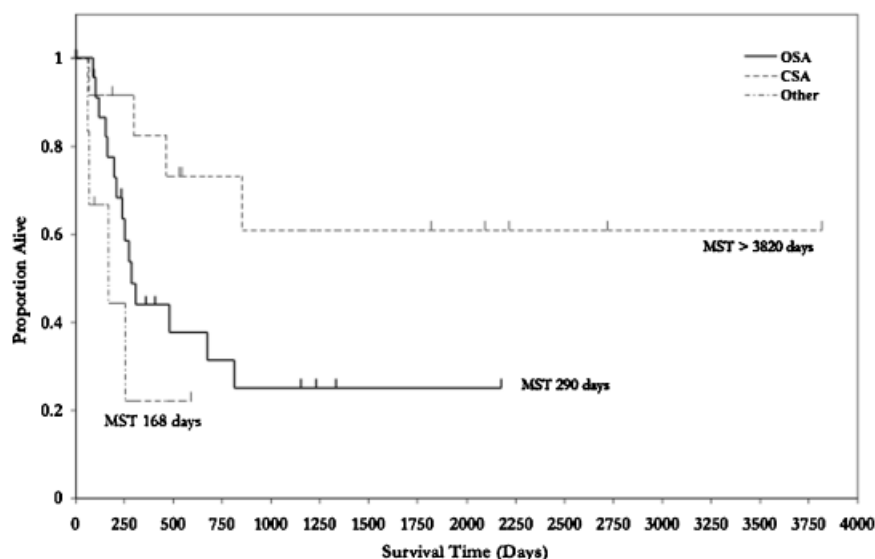


Fig 2. Kaplan–Meier survival curve for rib tumors in dogs. Dogs with chondrosarcomas had a significantly better estimated median survival time (> 3820 days, estimated mean 1301 days) compared with other tumor types (290 days for osteosarcoma and 256 days for hemangiosarcoma, $P = .0321$). OSA, osteosarcoma; CSA, chondrosarcoma; MST, median survival time.

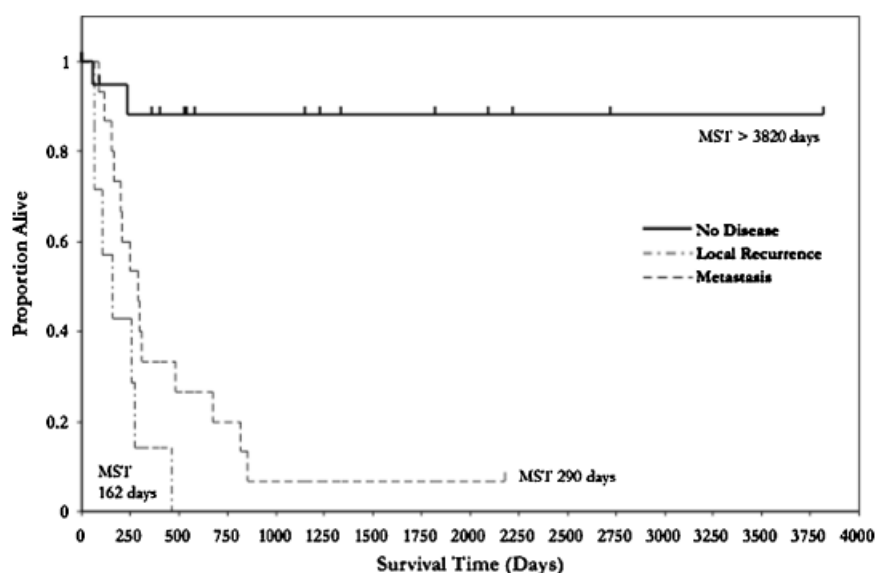


Fig 3. Kaplan–Meier survival curve for dogs with local tumor recurrence, distant metastasis, and no local tumor recurrence or metastasis. Estimated median survival time was significantly worse for dogs with local tumor recurrence (162 days, $P < .0001$) and metastasis (290 days, $P = .0009$) compared with dogs with no disease-related events (> 3820 days, mean 232 days). Tumor-related deaths were 28 and 55.6 times greater in dogs with local tumor recurrence and metastasis, respectively. MST, median survival time.

chronous or metastatic disease and possibly determination of dorsal and ventral surgical margins for rib resection.

Surgical excision of rib tumors should include 1 rib cranial and caudal to the tumor, 3 cm of grossly normal bone dorsal and ventral to the tumor in the affected rib(s), and 3 cm lateral margins around all contiguous soft tissues, including biopsy tracts, pleura, muscle, and fascia.^{3–6} Noninvolved muscle should be preserved for autogenous reconstruction.¹⁴ In some human and veterinary reports, excision of the entire affected rib has been recommended for treatment of primary malignant sarcomas because of intramedullary spread of the tumor beyond the grossly palpable extent of the tumor.^{14,17} Intramedullary extension is also common in dogs with appendicular OSA, and advanced imaging modalities, such as CT, MRI, and whole-body bone scans, are recommended before limb-sparing surgery to determine surgical margins because of increased accuracy of these modalities compared with radiographs.^{18–20} Intramedullary extension of the tumor resulting in incomplete excision was not noted in these dogs, but excision of the entire affected rib(s) is a prudent recommendation nonetheless. If there is evidence of either adhesion or invasion of the rib tumor into adjacent structures, such as the lungs, pericardium, diaphragm, or vertebra,³ then these should be resected en bloc with the rib tumor. Adhesions should be excised en bloc rather than disrupted, because 57% of the tumor-associated adhesions have histologic evidence of invasion.²¹ In our dogs, partial lung lobec-

tomy was performed in 25.6% of dogs and partial pericardectomy in 7.7% dogs. Partial lung lobectomy was performed more commonly in our dogs compared with other reports of chest wall resection for rib tumors in dogs.^{3–6,13} In humans, concurrent resection of any volume of lung with the rib tumor is associated with a significantly higher risk of respiratory complications and perioperative mortality²²; however, respiratory complications are rare in dogs after chest wall resection,^{11,17,23,24} and en bloc partial lung lobectomy was not associated with an increased risk of postoperative complications in our dogs and in another report.⁵

Oncologic Outcome

Oncologic outcome in these dogs was similar to that reported in other studies. Local tumor recurrence was diagnosed in 7 dogs overall (15.9%), including 3 dogs with OSA, 2 dogs with CSA, and 1 dog with HSA. This is comparable to a local tumor recurrence rate of 10–25% reported in other studies of chest wall resection for treatment of rib tumors in dogs.^{4–6,25} Overall, local tumor recurrence was reported in 25% of dogs with incompletely excised and 13.3% of dogs with completely excised tumors. Four of 8 dogs with incompletely excised tumors survived < 120 days after surgery and hence may not have had sufficient time to develop recurrence, as the median DFI for all tumor types in our study was 162 days. Decreased body weight significantly increased the risk of local tumor recurrence, but this was

most likely associated with an increased difficulty in achieving appropriate surgical margins in smaller dogs.

Unlike Pirkey-Ehrhart et al,⁵ we did not identify an association between incomplete excision of the rib tumor and local tumor recurrence, but local tumor recurrence was 6.7 times more likely when there was histologic evidence of tumor cells at the surgical margins. A type II statistical error is the most likely explanation for this lack of statistical significance. Complete surgical margins is the most important prognostic factor for local tumor recurrence and overall survival after chest wall resection of rib tumors in both dogs and humans.^{5,6,14} As a result, aggressive chest wall resection is essential to achieve optimum postoperative survival for dogs with rib tumors. Furthermore, the intra- and postoperative morbidity associated with chest wall resection and reconstruction is relatively low.^{3,5,12}

Primary rib OSA is the most common rib tumor in dogs. Estimated overall MST for dogs with primary rib OSA was 290 days. This included 19 dogs administered postoperative chemotherapy and 4 not administered chemotherapy. Postoperative survival time is short in dogs with rib OSA treated by chest wall resection alone with MSTs of 35–120 days and 6-month survival rates of $\leq 25\%$.^{2–6} Pirkey-Ehrhart et al⁵ showed that postoperative chemotherapy significantly improved median DFI and MST for dogs with primary rib OSAs from 60 to 225 days and 90 to 240 days, respectively. Despite the inclusion of a small number of dogs not administered chemotherapy, our estimated MST of 290 days supports the importance of postoperative chemotherapy in prolonging survival time in dogs with primary rib OSA.

Histologic subtype was not identified as a prognostic factor in our study despite 50% of the dogs with chondroblastic OSA being alive and disease-free 1335 and 2177 days postoperatively. However, the 2 remaining dogs with chondroblastic OSA died of lung metastasis at 200 and 256 days after surgery, and 1 dog alive and disease-free 2177 days postoperatively was diagnosed with lung metastasis 792 days after surgery, but these lesions resolved with an experimental gene therapy protocol. Histologic grade is prognostic for dogs with appendicular OSA,^{9,10} but was not prognostic for dogs with primary rib OSA.

Total serum ALP was identified as a prognostic factor in dogs with primary rib OSA. Estimated MST for dogs with total ALP within and greater than the reference interval was 675 and 210 days, respectively, with tumor-related deaths 7.9 times more likely in dogs with primary rib OSA and increased total ALP. Increased bone-specific and total serum ALP are also poor prognostic factors in dogs with appendicular OSA.^{7,8} The impact of increased ALP on survival time is probably specific to dogs with OSA, as ALP was commonly increased but not prognostic for dogs with rib CSA (50% of cases).

Estimated MST for dogs with primary rib CSA was not reached and was >3820 days (estimated mean, 1301 days), and survival was significantly better than that in all other primary rib tumors. Survival curves for dogs with primary rib CSA and OSA were not significantly different, but other studies have shown a significant difference in survival between these 2 types of primary rib tumors.^{3–5} Estimated MST for dogs with rib CSA was similar to other recent studies with reported MSTs of 1080 and 1750 days and was not reached (mean, 3097 days).^{5,6,11}

Histologic grade has prognostic importance in dogs and people with appendicular CSA,¹¹ but was not prognostic for primary rib CSA in our dogs or humans with rib CSA.²⁶ In our study, 2 dogs with rib CSA developed lung metastasis (16.7%) 299 and 853 days postoperatively. Chemotherapy is unlikely to provide a survival benefit in dogs with rib CSA, because the metastatic rate is low to moderate (8–50%) and, when metastasis does occur, it usually occurs late in the course of disease.^{3,5,11} Furthermore, chemotherapy has no benefit in preventing metastasis or prolonging survival in people with CSA.²⁷

In addition to tumor type and increased ALP, local tumor recurrence and distant metastasis were also identified as poor prognostic factors after chest wall resection for rib tumors in dogs. Estimated overall MSTs for dogs with no evidence of disease, local tumor recurrence, and distant metastasis were >3820 , 162, and 290 days, respectively. Furthermore, tumor-related deaths were 28 times more likely with local tumor recurrence and 55.6 times more likely with metastasis. Pirkey-Ehrhart et al⁵ also found that local tumor recurrence and distant metastasis resulted in a significantly worse outcome for dogs with primary rib tumors. This highlights the necessity of appropriate preoperative staging and aggressive surgical resection to excise rib tumors with complete histologic margins, and the use of postoperative chemotherapy for rib tumors that are associated with a high risk of metastasis, such as OSA.

REFERENCES

1. Ling GV, Morgan JT, Pool RR: Primary bone tumors in the dog: a combined clinical, radiographic, and histologic approach to early diagnosis. *J Am Vet Med Assoc* 165:55–67, 1974
2. Feeney DA, Johnston GR, Grindem CB, et al: Malignant neoplasia of canine ribs: clinical, radiographic, and pathologic findings. *J Am Vet Med Assoc* 180:927–933, 1982
3. Matthiesen DT, Clark GN, Orsher RJ, et al: En bloc resection of primary rib tumors in 40 dogs. *Vet Surg* 21:201–204, 1992
4. Montgomery RD, Henderson RA, Powers RD, et al: Retrospective study of 26 primary tumors of the osseous thoracic wall in dogs. *J Am Anim Hosp Assoc* 29:68–72, 1993

5. Pirkey-Ehrhart N, Withrow SJ, Straw RC, et al: Primary rib tumors in 54 dogs. *J Am Anim Hosp Assoc* 31:65–69, 1995
6. Baines SJ, Lewis S, White RAS: Primary thoracic wall tumours of mesenchymal origin in dogs: a retrospective study of 46 cases. *Vet Rec* 150:335–339, 2002
7. Ehrhart N, Dernell WS, Hoffmann WE, et al: Prognostic importance of alkaline phosphatase activity in serum from dogs with appendicular osteosarcoma: 75 cases (1990–1996). *J Am Vet Med Assoc* 213:1002–1006, 1998
8. Garzotto CK, Berg J, Hoffmann WE, et al: Prognostic significance of serum alkaline phosphatase activity in canine appendicular osteosarcoma. *J Vet Intern Med* 14:587–592, 2000
9. Kirpensteijn J, Kik M, Rutterman GR, et al: Prognostic significance of a new histologic grading system for canine osteosarcoma. *Vet Pathol* 39:240–246, 2002
10. Loukopoulos P, Robinson WF: Clinicopathological relevance of tumour grading in canine osteosarcoma. *J Comp Pathol* 136:65–73, 2007
11. Waltman SS, Seguin B, Cooper BJ, et al: Clinical outcome of nonnasal chondrosarcoma in dogs: thirty-one cases (1986–2003). *Vet Surg* 36:266–271, 2007
12. Liptak JM, Dernell WS, Rizzo SA, et al: Reconstruction of chest wall defects following rib tumor resection: a comparison of autogenous, prosthetic, and composite techniques in 44 dogs. *Vet Surg* 37:479–487, 2008
13. Brodey RS, McGrath JT, Reynolds H: A clinical and radiological study of canine bone neoplasms. *J Am Vet Med Assoc* 134:53–71, 1959
14. Incarbone M, Pastorino U: Surgical treatment of chest wall tumors. *World J Surg* 25:218–230, 2001
15. Nemanic S, London CA, Wisner ER: Comparison of thoracic radiographs and single breath-hold helical CT for detection of pulmonary nodules in dogs with metastatic neoplasia. *J Vet Intern Med* 20:508–515, 2006
16. Jankowski MK, Steyn PF, Lana SE, et al: Nuclear scanning with ^{99m}Tc-HDP for the initial evaluation of osseous metastasis in canine osteosarcoma. *Vet Comp Oncol* 1:152–158, 2003
17. Halfacree ZJ, Baines SJ, Lipscomb VJ, et al: Use of a latissimus dorsi myocutaneous flap for one-stage reconstruction of the thoracic wall after en bloc resection of primary rib chondrosarcoma in five dogs. *Vet Surg* 36:587–592, 2007
18. Leibman NF, Kuntz CA, Steyn PF, et al: Accuracy of radiography, nuclear scintigraphy, and histopathology for determining the proximal extent of distal radial osteosarcoma in dogs. *Vet Surg* 30:240–245, 2001
19. Davis GJ, Kapatkin AS, Craig LE, et al: Comparison of radiography, computed tomography, and magnetic resonance imaging for evaluation of appendicular osteosarcoma in dogs. *J Am Vet Med Assoc* 220:1171–1176, 2002
20. Wallack ST, Wisner ER, Werner JA, et al: Accuracy of magnetic resonance imaging for estimating intramedullary osteosarcoma extent in preoperative planning of canine limb-salvage procedures. *Vet Radiol Ultrasound* 43:432–441, 2002
21. Nogueras JJ, Jagelman DG: Principles of surgical resection. Influence of surgical technique on treatment outcome. Colorectal cancer. *Surg Clin North Am* 73:103–116, 1993
22. Weyant MJ, Bains MS, Venkatraman E, et al: Results of chest wall resection and reconstruction with and without rigid prosthesis. *Ann Thorac Surg* 81:279–285, 2006
23. Mathes SJ: Chest wall reconstruction. *Clin Plast Surg* 22:187–198, 1995
24. Novoa N, Benito P, Jiménez MF, et al: Reconstruction of chest wall defects after resection of large neoplasms: ten-year experience. *Interact Cardiovasc Thorac Surg* 4:250–255, 2005
25. Bowman KLT, Birchard SJ, Bright RM: Complications associated with the implantation of polypropylene mesh in dogs and cats: a retrospective study of 21 cases (1984–1996). *J Am Anim Hosp Assoc* 34:225–233, 1998
26. Fong YC, Pairolo PC, Sim FH, et al: Chondrosarcoma of the chest wall. *Clin Orthop Relat Res* 427:184–189, 2004
27. Malawer MM, Helman LJ, O'Sullivan B: Sarcomas of bone, in De Vita VT, Hellman S, Rosenberg SA (eds): *Cancer: Principles & Practice of Oncology* (ed 7). Philadelphia, PA, Lippincott Williams & Wilkins, 2005, pp 1638–1686