Cranial mediastinal carcinomas in nine dogs*

J. M. Liptak[1†], D. A. Kamstock[2], W. S. Dernell[1], E. J. Ehrhart[2], S. A. Rizzo[1] and S. J. Withrow[1]

[1]Animal Cancer Center College of Veterinary Medicine and Biomedical Sciences, Colorado State University, Fort Collins, CO, USA
[2]Department of Microbiology, Immunology, and Pathology, College of Veterinary Medicine and Biomedical Sciences, Colorado State University, Fort Collins, CO, USA

Abstract

Nine dogs were diagnosed with cranial mediastinal carcinomas. Based on histological and immunohistochemical analysis, four dogs were diagnosed with ectopic follicular cell thyroid carcinomas, one dog with ectopic medullary cell thyroid carcinoma, two dogs with neuroendocrine carcinomas and two dogs with anaplastic carcinomas. Clinical signs and physical examination findings were associated with a space-occupying mass, although one dog was diagnosed with functional hyperthyroidism. Surgical resection was attempted in eight dogs. The cranial mediastinal mass was invasive either into the heart or into the cranial vena cava in three dogs. Resection was complete in six dogs and unresectable in two dogs. All dogs survived surgery, but four dogs developed pulmonary thromboembolism and two dogs died of respiratory complications postoperatively. Adjunctive therapies included pre-operative radiation therapy ($n = 1$) and postoperative chemotherapy ($n = 3$). Three dogs had metastasis at the time of diagnosis, but none developed metastasis following surgery. The overall median survival time was 243 days. Local invasion, pleural effusion and metastasis did not have a negative impact on survival time in this small case series.

Keywords
carcinoma, dog, ectopic thyroid, mediastinal, neuroendocrine, thymic

Introduction

Thymoma and lymphosarcoma are the two most common cranial mediastinal tumours in dogs.[1,2] Sarcomas and ectopic thyroid carcinomas have also been reported, but these are very rare.[3] Ectopic thyroid tissue has identical physiological and pathological behaviour as normal thyroid glands.[4] Thyroid tissue is composed of two basic cell types: follicular and parafollicular cells. Follicular cell thyroid carcinomas are more common in dogs and usually present with a palpable mass but occasionally may be associated with functional hyperthyroidism.[5,6] Parafollicular cell thyroid carcinomas, which are also known as medullary or C-cell carcinomas, are considered neuroendocrine (NE) carcinomas and have a biological behaviour similar to that of follicular cell thyroid carcinomas.[5] Medullary cell thyroid carcinomas are often well-circumscribed and hence more amenable to surgical excision.[5,7] The prognosis following appropriate treatment is dependent on tumour size and degree of invasion into adjacent tissue.[8–11]

NE carcinomas have not previously been reported in the cranial mediastinum of dogs and are very rare in humans.[12–15] NE carcinomas are also known as amine precursor uptake and decarboxylation tumours because of their potential to produce

Correspondence address:
Julius M. Liptak
Alta Vista Animal Hospital
2616 Bank Street
Ottawa, Ontario, Canada
K1T 1M9
e-mail: jliptak@uoguelph.ca

*This study was presented in part at the 2nd Annual Meeting of the Society of Veterinary Soft Tissue Surgeons, Breckenridge, Colorado, June 2003, and the 56th Annual Meeting of the American College of Veterinary Pathologists, Boston, Massachusetts, December 2005.
†Present address: Alta Vista Animal Hospital, 2616 Bank Street, Ottawa, Ontario, Canada K1T 1M9.

© 2008 The Authors. Journal compilation © 2008 Blackwell Publishing Ltd

peptides, amines, kinins and prostaglandins.[14] In humans, thymic NE carcinomas arise from thymic Kulchitsky cells, which are neuroectodermal cells of foregut origin within the thymus.[12,14] Thymic NE carcinomas are usually locally invasive but metastasis to bone, lymph nodes, skin and liver has also been reported.[12,13] Unlike NE carcinomas in other locations, thymic NE carcinomas in humans are frequently not functional.[12] Hyperadrenocorticism is reported in 38% and multiple endocrine neoplasia type I or II in up to 18% of humans with thymic NE carcinoma.[12,13] Prognosis is dependent on degree of differentiation and local tumour control, with prognosis worse in individuals with incomplete resection and local tumour recurrence.[13]

The purpose of this study was to describe the clinical findings, surgical treatment and postoperative and oncological outcome in dogs with carcinomas of the cranial mediastinum.

Materials and methods

The medical and histopathology records at Colorado State University Veterinary Teaching Hospital were retrospectively reviewed for dogs with mediastinal disease from July 1995 to June 2003. Dogs were included if the tumour was visualized arising primarily from the cranial mediastinal space, at either surgery or necropsy, and histologically confirmed as a carcinoma. Exclusion criteria included diagnosis of a mediastinal carcinoma secondary to direct extension from an adjacent lung carcinoma and noncarcinoma tumours of the cranial mediastinum.

The records of each dog were reviewed and information recorded on signalment, presenting signs, physical examination findings, haematology and serum biochemistry, imaging techniques and findings, surgical approach and intra-operative findings, postoperative complications, adjuvant treatments and outcome. The outcome parameters measured included local tumour recurrence, metastasis and survival time. Survival time was defined as the period from diagnosis of mediastinal carcinoma to death. The cause of death was recorded and considered to be tumour related if caused by local tumour recurrence or progression or distant metastasis. Death was not considered tumour related if caused by complications associated with surgical or adjunctive treatments.

A panel of immunohistochemical (IHC) stains was used to assess the original haematoxylin and eosin (H&E) histological diagnosis and differentiate between the different types of mediastinal carcinoma, particularly ectopic thyroid carcinoma and nonthyroid carcinoma. Archived formalin-fixed tissue samples were stained for thyroglobulin, calcitonin, thyroid transcription factor-1 (TTF-1), synaptophysin and chromogranin. Thyroglobulin, calcitonin and TTF-1 were used to identify carcinomas of thyroid origin, where thyroglobulin is specific for thyroid follicular cells, calcitonin is specific for thyroid medullary (parafollicular or C) cells and TTF-1 nonspecifically stains for both follicular and medullary cells.[5,16,17] Synaptophysin and chromogranin are generic stains for cells of NE origins and are used to identify NE carcinomas.[12] Thyroid medullary cells are NE cells and will be immunoreactive with all the above markers except thyroglobulin.[5,17] The level of staining was graded as either negative or positive, and positive IHC staining was further classified as weakly or strongly positive in some cases. Tumours that did not show immunoreactivity across the panel of markers were defined as anaplastic as the histogenesis remained undetermined.

Kaplan–Meier survival analysis with log rank was used to calculate the overall median survival time (MST) and to assess whether pre-operative (pleural effusion or metastasis at diagnosis) and intra-operative findings (tumour type, gross tumour invasion, tumour size and tumour resectability) and postoperative complications influenced survival time. Pearson's chi-squared test was used to analyse the associations between the above factors and peri-operative death. Significance was established with a P value <0.05.

Results

Nine dogs were diagnosed with primary mediastinal carcinoma between July 1995 and June 2003. Of these, four dogs were diagnosed with NE carcinoma and five with ectopic thyroid carcinoma. During the same time period, 34 dogs were

histologically diagnosed with primary mediastinal diseases other than carcinoma. These included thymoma ($n = 14$), nonlymphoid sarcomas ($n = 6$ [osteosarcoma, $n = 3$; liposarcoma, $n = 1$; soft tissue sarcoma, $n = 1$ and undifferentiated sarcoma, $n = 1$]), lymphosarcoma ($n = 4$), bacterial granuloma ($n = 3$) or granulomatous steatitis ($n = 2$) and miscellaneous benign and malignant diseases (mediastinal cyst, fibroma, lipoma, chemodectoma and suspected mast cell tumour; $n = 1$ each).

A variety of breeds were represented, including four mixed breed dogs and one each of Sheltie, German Shepherd, Labrador Retriever, Keeshond and Rough-Coated Collie. The median body weight was 22.4 kg (mean, 26.7 kg; range, 18.2–37.7 kg). The median age was 10 years (mean, 9.7 years; range, 4–13 years). All dogs were neutered, with five female dogs and four male dogs.

Presenting clinical signs were variable. Dyspnoea was the most common clinical sign and was present in six dogs. Other clinical signs included regurgitation ($n = 2$), inappetence ($n = 2$), coughing ($n = 1$), exercise intolerance ($n = 1$), weakness ($n = 1$) and lameness ($n = 1$). The dog presenting with thoracic limb lameness had a mediastinal carcinoma invading into an adjacent rib and vertebrae. A cranial mediastinal mass was an incidental finding on thoracic radiographs in two dogs, one during a geriatric health check and the other during follow-up evaluation after completing a course of chemotherapy for nonmediastinal lymphosarcoma.

Physical examination findings were also variable. Heart sounds were muffled in four dogs, three dogs were panting, two dogs had decreased bronchovesicular sounds, two dogs had evidence of generalized muscle wastage, one dog had neck pain and one dog was recumbent. In general, dogs presenting with either panting or decreased heart and lung sounds were later diagnosed with large cranial mediastinal masses and/or pleural effusion. In some dogs, the physical examination findings did not necessarily correlate with the size of the mediastinal mass or presence of pleural effusion. For instance, muscle wastage was the only reported finding in one dog with a very large cranial mediastinal mass, whereas muffled heart sounds were detected in another dog with a small cranial mediastinal mass and no pleural effusion.

Haematology and serum biochemistry were analyzed in all dogs. Haematological abnormalities included mature neutrophilia ($n = 2$, 14.1×10^9 cells μL^{-1} to 23.0×10^9 cells μL^{-1}, reference range $2.6–11.0 \times 10^9$ cells μL^{-1}), neutrophilia with left shift ($n = 1$, 0.7×10^9 cells μL^{-1}, reference range $<0.2 \times 10^9$ cells μL^{-1}), lymphopaenia ($n = 4$, 0.4×10^9 cells μL^{-1} to 1.0×10^9 cells μL^{-1}, reference range $1.0–4.8 \times 10^9$ cells μL^{-1}) and thrombocytopaenia ($n = 2$, 130 to $\times 10^3$ cells μL^{-1} 163×10^3 cells μL^{-1}, reference range 200 to $\times 10^9$ cells μL^{-1} to 500×10^9 cells μL^{-1}). Anaemia was not detected in any dog. Serum biochemical abnormalities included hypo-albuminaemia ($n = 2$, 2.3–2.8 g dL^{-1}, reference range 2.9–4.0 g dL^{-1}), hypoproteinaemia ($n = 1$, 4.7 g dL^{-1}, reference range 5.3–7.2 g dL^{-1}), hyperglycaemia ($n = 2$, 134–201 mg dL^{-1}, reference range 75–130 mg dL^{-1}) and increased alkaline phosphatase (280–2391 IU L^{-1}, reference range 20–142 IU L^{-1}), alanine transferase (458–913 IU L^{-1}, reference range 10–110 IU L^{-1}) and aspartate transferase (46–121 IU L^{-1}, reference range 16–50 IU L^{-1}) levels in three dogs. One dog had an increased serum thyroxine level (114 nmol L^{-1}, reference range 15–67 nmol L^{-1}).

Modalities used to image the thoracic cavity included radiographs ($n = 9$), ultrasound ($n = 6$) and computed tomography (CT) scans ($n = 1$). A cranial mediastinal mass was evident in all cases, regardless of the imaging modality used. The cranial mediastinal mass varied in size from 2.8×3.8 cm

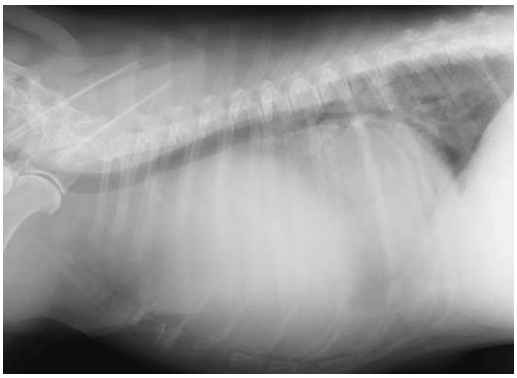

Figure 1. Lateral thoracic radiograph showing a large ectopic follicular thyroid carcinoma in the cranial mediastinum of a dog causing caudodorsal displacement of the cardiac silhouette and lungs and dorsal elevation of the trachea.

to 20 × 30 cm (Fig. 1). In one dog, lytic lesions in the second right rib and first and second thoracic vertebrae were noted on thoracic radiographs and confirmed on CT scans. A single pulmonary metastatic lesion was suspected in another dog. Four dogs also had evidence of pleural effusion on thoracic radiographs. Thoracocentesis was performed in two dogs, and neither had evidence of neoplastic cells on cytological examination of the pleural fluid. Ultrasound was used to either confirm the presence of a cranial mediastinal mass ($n = 3$) or further characterize the mass as well circumscribed and avascular ($n = 2$) or cavitated ($n = 1$). In addition, one dog had evidence of multiple liver nodules that were diagnosed as nodular hyperplasia based on cytology of ultrasound-guided aspirates. Nuclear scintigraphy scans, using radiolabelled ^{131}iodine, were performed in two dogs. In one dog with increased serum thyroxine levels, the scan was positive with evidence of a functional mass in the cranial mediastinum. The scan was negative in the remaining dog, and this dog was later diagnosed with a nonthyroid carcinoma.

Ultrasound-guided ($n = 6$) or blind percutaneous ($n = 2$) aspirates of the cranial mediastinal mass were performed in eight dogs. Based on cytological examination of these aspirates, four dogs were diagnosed with carcinoma, two with NE carcinoma and one with suppurative inflammation, and the aspirate in one dog was nondiagnostic.

Surgery was performed in eight dogs (Table 1). One dog with evidence of local bone invasion into an adjacent rib and vertebrae was euthanased at diagnosis. Of the eight dogs treated surgically, a cranial median sternotomy ($n = 7$) was the preferred approach, although a lateral intercostal thoracotomy was performed in one dog. The cranial mediastinal mass invaded vascular structures in three dogs. In two of these dogs, the cranial mediastinal mass could not be resected because of invasion into the heart or major vessels. In another dog with tumour invasion into the cranial vena cava and tumour thrombus formation within the cranial vena cava, the cranial mediastinal mass was resected *en bloc* with the tumour thrombus and the caval defect was repaired primarily. In the remaining five dogs, the cranial mediastinal mass was well circumscribed and subjectively assessed as being either highly vascular (Fig. 2) in two dogs or avascular (Fig. 3) in three dogs. Thus, the cranial mediastinal mass was completely resected in six dogs and nonresectable in two dogs. In addition to the cranial mediastinal mass, multifocal lung lesions were detected in two dogs, one of which was suspected to

Table 1. Surgical and oncological outcome for dogs with mediastinal carcinomas

Case	Surgical approach	Complete resection	Metastasis at diagnosis	Other therapy	Survival time (days)	Cause of death
1	Sternotomy	Yes	No	Doxorubicin	147	Nontumour: heart failure
2	Thoracotomy	No[a]	No	Doxorubicin	512	Tumour: progressive disease
3	Sternotomy	No[a]	Mediastinal LN	No	607	Tumour: progressive disease
4	Sternotomy	Yes	Lungs	No	243	Tumour: metastasis
5	Sternotomy	Yes	No	No	5	Lost to follow-up
6	No	—	No	No	1	Tumour: bone invasion
7	Sternotomy	Yes	No	No	301	Nontumour: intervertebral disc disease
8	Sternotomy	Yes	Lungs	Radiation therapy[b]	3	Nontumour: PTE
9	Sternotomy	Yes	No	No	13	Nontumour: failure to wean off ventilator

LN, lymph node.
[a]Tumour invaded heart and vascular structures.
[b]Pre-operative radiation therapy with four weekly fractions of 6 Gy.

Figure 2. An intraoperative image of a large ectopic follicular thyroid carcinoma in the cranial mediastinum of a dog. Note the highly vascular nature of the mass and the similarities in gross morphological appearance of this ectopic thyroid carcinoma to orthotopic thyroid carcinomas in dogs.

Figure 3. The gross appearance of an ectopic follicular thyroid carcinoma (same as Fig. 1) following complete surgical resection. Note that the mass is well circumscribed, noninvasive and poorly vascular. The morphological appearance of this mass shares some similarities with noninvasive orthotopic thyroid carcinomas in dogs.

have metastasis on pre-operative thoracic radiographs, and an enlarged mediastinal lymph node in one dog.

All dogs survived surgery. Postoperative analgesia included fentanyl continuous rate infusion (CRI) ($n = 8$), ketamine CRI ($n = 1$), intrapleural local anaesthesia ($n = 3$) and intermittent intravenous xylazine ($n = 2$) or hydromorphone ($n = 1$). Thoracostomy tubes were placed in all dogs and maintained for a median of 22 h postoperatively (mean 61.6 h, range 18–288 h). Supplemental oxygen was administered to five dogs, including nasal oxygen in four dogs and ventilatory support in one dog. Four dogs had no postoperative complications and four dogs had complications. The most common complication was pulmonary thromboembolism (PTE, $n = 4$), which was suspected when dogs experienced postoperative dyspnoea or respiratory difficulties in combination with decreased arterial oxygen tension and increased arterial carbon dioxide tension on blood gas analyses. These dogs were treated with oxygen supplementation, heparin (10 IU kg^{-1} every 6 h) and cage rest. Two dogs with PTE survived and two dogs died because of respiratory complications. One dog with PTE required ventilatory support but was unable to be weaned off the ventilator and was euthanased 13 days postoperatively. This dog was diagnosed with gastric dilatation–volvulus 5 days postoperatively, which was treated with gastric derotation and an incisional gastropexy. Both surviving dogs with PTE also had other complications including hypotension ($n = 1$), pulmonary oedema ($n = 1$) and anaemia ($n = 1$). In one dog with pre-operative hyperthyroidism, serum thyroxine levels decreased to below the reference range, while serum levels of thyroid-stimulating hormone were increased. Thyroid hormone supplementation was not given because the dog was not clinically hypothyroid. Hence, six dogs survived surgery and two dogs died as a result of surgical complications, resulting in a peri-operative mortality rate of 25%.

Three dogs received adjunctive therapies. One dog was treated with four fractions of 6 Gy pre-operatively, on days 0, 7, 21 and 28, in an attempt to downstage the tumour size prior to surgery and increase the likelihood of complete resection. The radiographic diameter of the cranial mediastinal mass decreased from 20 to 15 cm with radiation

therapy, and the tumour was completely resected 14 days after completing the radiation course. However, this dog died of respiratory arrest secondary to PTE postoperatively. Two dogs with nonmetastatic mediastinal carcinomas were treated with doxorubicin (30 mg m^{-2} intravenously once every 3 weeks). One dog died of heart failure (secondary to congenital tricuspid regurgitation) after receiving four doses of doxorubicin. The remaining dog, which had an incompletely resected mediastinal carcinoma because of invasion into the heart, received the targeted five doses of doxorubicin without complications.

The original H&E diagnoses included five dogs with ectopic thyroid carcinoma and four dogs with NE carcinoma (Table 2). The thyroid carcinomas were not subclassified according to their cell of origin based on original H&E diagnoses, and two of the NE carcinomas were suspected to be of thyroid origin. Based on IHC staining, four of the tumours diagnosed as thyroid carcinomas were consistent with a thyroid carcinoma of follicular cell origin (thyroglobulin and TTF-1 positive, and calcitonin negative), while the remaining thyroid carcinoma was reclassified as a nonthyroid NE carcinoma (synaptophysin and chromogranin positive, and thyroglobulin, TTF-1 and calcitonin negative). Of the four NE carcinomas, one was confirmed as an NE carcinoma (synaptophysin and chromogranin positive, and thyroglobulin, TTF-1 and calcitonin negative), one was reclassified as a thyroid carcinoma of medullary cell origin (synaptophysin, chromogranin, calcitonin and TTF-1 positive, and thyroglobulin negative) and two were reclassified as anaplastic carcinomas (synaptophysin, chromogranin, calcitonin, TTF-1 and thyroglobulin negative). As medullary cells are NE cells, medullary cell thyroid carcinomas are NE tumours of thyroid origin.[5,17] The positive correlation rate between histological and IHC diagnoses was 80% for dogs originally diagnosed with ectopic thyroid carcinomas and 50% for dogs originally diagnosed with NE carcinomas if the medullary cell thyroid carcinoma is also considered an NE carcinoma.

Three dogs had metastatic disease at diagnosis, two with pulmonary metastasis and one with metastasis to the mediastinal lymph node. A follicular cell thyroid carcinoma, anaplastic carcinoma and NE carcinoma were diagnosed in each of these dogs with metastatic disease, respectively. No dog developed either local tumour recurrence or metastatic disease following surgical treatment. One dog was lost to follow-up 5 days postoperatively after discharge from the hospital. One dog with a locally invasive anaplastic carcinoma was euthanased 1 day after diagnosis without surgical treatment. Two dogs died as a result of surgical complications 3 and 13 days postoperatively. Two dogs with incompletely resected mediastinal carcinomas were euthanased 512 and 607 days postoperatively because of the clinical signs associated with progression of local disease. One dog was euthanased because of progression of pulmonary metastases 243 days after surgery. One dog died of unspecified neurological

Table 2. Histological and IHC analysis of mediastinal carcinomas in dogs

Case	H&E diagnosis	Thyroglobulin	Calcitonin	TTF-1	Synaptophysin	Chromogranin	IHC diagnosis
1	NE carcinoma	N	N	N	N	N	Anaplastic carcinoma
2	Thyroid carcinoma	P	N	SP	—	—	Follicular thyroid carcinoma
3	NE carcinoma	N	N	N	P	P	NE carcinoma
4	NE carcinoma	N	N	N	N	N	Anaplastic carcinoma
5	Thyroid carcinoma	P	N	SP	—	—	Follicular thyroid carcinoma
6	Thyroid carcinoma	N	N	N	P	P	NE carcinoma
7	Thyroid carcinoma	P	N	P	—	—	Follicular thyroid carcinoma
8	Thyroid carcinoma	WP	N	P	—	—	Follicular thyroid carcinoma
9	NE carcinoma	N	SP	P	P	P	Medullary thyroid carcinoma

N, negative; P, positive; SP, strong positive; WP, weak positive.

disease 301 days postoperatively. The overall MST for all dogs with mediastinal carcinomas was 243 days (range 1–607 days). The survival times for treated dogs ranged from 5 to 512 days for dogs with ectopic follicular cell thyroid carcinomas ($n = 4$), 147 to 243 days for dogs with anaplastic carcinomas ($n = 2$) and 3 to 607 days for dogs with NE carcinomas ($n = 2$), including one dog with an ectopic medullary thyroid carcinoma surviving for 13 days postoperatively.

In this limited number of cases, pleural effusion, metastasis at diagnosis, tumour type, tumour invasion into adjacent structures, tumour resection and postoperative complications did not significantly affect either peri-operative death or survival time. The MST for dogs with pleural effusion at presentation was 243 days and was not significantly different from the MST of 512 days for dogs without pleural effusion ($P = 0.809$). The MST for dogs with metastasis at diagnosis was 512 days and was not significantly different from the MST of 13 days for dogs without metastasis ($P = 0.352$). The MST for dogs with evidence of tumour invasion into adjacent organs or structures was 243 days and was not significantly different from the MST of 512 days for dogs with noninvasive carcinomas ($P = 0.620$).

Discussion

Carcinomas of the cranial mediastinum are rare in dogs. The two most commonly reported tumours of the cranial mediastinum in dogs are lymphosarcoma and thymoma.[1,2] During the 8-year study period of this report, 9 dogs were diagnosed with carcinomas, 14 with thymomas, 4 with lymphosarcoma, and 6 with a variety of nonlymphoid sarcomas in the cranial mediastinum. The two major differences in the spectrum of tumour types identified in our review of cranial mediastinal tumours are the preponderance of carcinomas and under-representation of lymphosarcomas. Lymphosarcomas are most probably under-reported because our review was designed to identify surgical cases and the majority of dogs with cranial mediastinal lymphosarcoma are diagnosed by nonsurgical methods.

Ectopic thyroid carcinomas have been reported in the cranial mediastinum of dogs, but these usually arise from the heart base and then compress or invade structures of the cranial mediastinum rather than arising primarily from the cranial mediastinum.[3] The formation of accessory thyroid tissue is common during thyroid development in dogs, with islets of rapidly proliferating cells of the thyroid primordial separating from the main mass and becoming incorporated into the developing structures of the brachium and thorax.[18] Ectopic thyroid tissue has identical physiological and pathological behaviour as normal thyroid glands.[4] As a result, thyroid carcinomas can arise from ectopic thyroid tissue in the tongue, along the trachea distant to the thyroid glands, and in the thoracic inlet, cranial mediastinum and pericardium, and along the descending aorta and heart base.[3,6] There are a number of similarities in the morphological characteristics and biological behaviour of thyroid carcinomas and ectopic thyroid carcinomas diagnosed in the present series.

The most important clinical factor in determining surgical resectability and prognosis in dogs with orthotopic thyroid carcinomas is whether the tumour is noninvasive and mobile or invasive and fixed.[5,8] In the present series, five dogs were diagnosed with either follicular or medullary cell thyroid carcinomas and two of these dogs had evidence of local invasion into the cranial vena cava and heart. Subclassification of thyroid tumours into medullary or follicular cell origin may also determine surgical resectability as medullary cell thyroid carcinomas are usually well encapsulated and more amenable to surgical resection.[5,7] The case numbers were too small in the present study to make a meaningful comparison, but one dog with an ectopic medullary cell thyroid carcinoma and two of the four dogs with ectopic follicular cell thyroid carcinomas had well-circumscribed tumours. An additional two dogs had highly vascular tumours, and this is another characteristic of thyroid carcinomas in dogs.[6] The metastatic rate for thyroid carcinomas is variable, ranging from 16 to 40%, and is dependent on tumour size and invasiveness.[5,9,10] One dog was diagnosed with pulmonary metastasis, and this dog had the largest measured tumour in the present series, with a diameter of 20 cm.

NE and anaplastic carcinomas have not previously been reported in the cranial mediastinum of

dogs and are very rare in humans.[12–15] Thymic NE carcinomas in humans are usually locally invasive but metastasis to bone, lymph nodes, skin and liver has also been reported.[12,13] Both dogs diagnosed with NE carcinomas in the present series had locally invasive tumours and one dog had metastasis to the mediastinal lymph node. Thymic NE carcinomas in humans are frequently nonfunctional,[12] and neither dog in our series had evidence of concurrent endocrinopathy. Prognosis is dependent on degree of differentiation and local tumour control, with prognosis worse in individuals with incomplete resection and local tumour recurrence.[13]

Immunohistochemistry is recommended for the definitive diagnosis of heart-base tumours and subclassification of thyroid carcinomas because differentiating ectopic thyroid carcinomas from other heart-base tumours and distinguishing between follicular and medullary cell thyroid carcinomas based on histological criteria alone may be challenging.[3,5,7,9,16] In the present series, we used thyroglobulin, TTF-1 and calcitonin to identify tumours as being of thyroid origin.[16,17,19] Follicular cell thyroid carcinomas were diagnosed when tumours stained positively for thyroglobulin and TTF-1 but not for calcitonin. Medullary cell thyroid carcinomas were diagnosed when tumours stained positively for calcitonin and TTF-1 but not for thyroglobulin. Based on this panel of IHC stains, four dogs were diagnosed with follicular cell thyroid carcinomas and one with a medullary cell thyroid carcinoma. The original histological diagnosis of thyroid carcinoma correlated with the IHC diagnosis in four dogs, with one dog originally diagnosed with an ectopic thyroid carcinoma being reclassified as a nonthyroid NE carcinoma.

Synaptophysin and chromogranin were used to confirm NE tumours in dogs with medullary cell thyroid and nonthyroid carcinomas.[13,15] A panel of NE markers is preferred for the diagnosis of NE tumours because immunoreactivity to a single stain is inconsistent.[15] For example, chromogranin stained positively in 30%, synaptophysin in 50% and neuron-specific enolase in 80% of hepatic NE carcinomas.[15] In the present series, nonthyroid NE carcinomas were diagnosed when tumours stained positively for synaptophysin and chromogranin but not for thyroglobulin, TTF-1 or calcitonin. Medullary cell thyroid carcinomas are also classified as NE tumours,[5,17] and this was diagnosed when tumours stained positively for synaptophysin and chromogranin as well as for TTF-1 and calcitonin but not for thyroglobulin. Anaplastic carcinomas were diagnosed when tumours did not stain positively with any of the IHC markers. Based on this panel of IHC stains, two dogs each were diagnosed with NE and anaplastic carcinomas and one dog was confirmed with a medullary cell thyroid carcinoma. The original histological diagnosis of NE carcinoma correlated with the IHC diagnosis in two dogs, one with an NE carcinoma and one with a medullary cell thyroid carcinoma. One dog originally diagnosed with a thyroid carcinoma was reclassified as an NE carcinoma, and two dogs originally diagnosed with NE carcinomas were reclassified as anaplastic carcinomas.

The cell of origin of the anaplastic carcinomas is unknown. These may have originated from thymic, ectopic thyroid or neuroendocrine cells. These tumours were classified as anaplastic based on the lack of immunoreactivity across the panel of IHC markers and not because of cytomorphological anaplasia. In humans, thymic carcinomas are malignant epithelial tumours of the thymus and are characterized by a high degree of cellular atypia and an aggressive biological behaviour.[12,14] Thymic carcinomas express the cytokeratin marker CD5, and this can be used to differentiate thymic from nonthymic carcinomas.[12] NE can also be anaplastic, but the vast majority are positive for NE markers regardless of their degree of anaplasia.[12,13] We did not use neuron-specific enolase in our panel of IHC markers, and this has been shown to be a very sensitive marker for the diagnosis of NE carcinomas of the canine liver[15] and anaplastic NE carcinomas in humans.[20] Hence, it is possible that the two dogs with anaplastic carcinomas may have been diagnosed with NE carcinomas if this marker was used. Other researchers have cautioned the use of this stain because neuron-specific enolase is not specific for the diagnosis of NE carcinomas and is expressed in a wide variety of tissues not containing NE cells.[19] Anaplastic NE carcinomas in humans also express chromogranin and synaptophysin,[13,20] which was not observed in the two dogs diagnosed with anaplastic carcinomas in the

present study. In contrast, in both dogs and humans, anaplastic thyroid carcinomas do not express either TTF-1 or thyroglobulin.[17] As a result, the anaplastic carcinomas described herein most probably represent anaplastic thyroid carcinomas because of the lack of positive staining for all the IHC markers.

The clinical presentation and biological behaviour of cranial mediastinal carcinomas in dogs were similar to those in dogs with orthotopic thyroid carcinomas and other cranial mediastinal tumours.[5,21] Middle to older aged, large breed dogs were most commonly affected. Clinical signs associated with a space-occupying mass, such as dyspnoea and exercise intolerance, were the most frequent reasons for presentation.[1,5,21] Thyroxine levels were not routinely tested in the present series, but one dog had an increased serum thyroxine level. Functional thyroid carcinomas have been reported in dogs,[22] but the incidence is less than 25%, and the clinical sequelae to functional hyperthyroidism are less severe in dogs than those reported in cats with thyroid tumours.[5,6,23,24]

A CT scan was performed in only one dog in the present series, but it is the preferred imaging modality for the diagnosis, local staging and evaluation of lung metastasis in both dogs and humans with cranial mediastinal tumours.[25] Contrast-enhanced CT scans provide superior three-dimensional information on local tumour characteristics, such as invasion into the cranial vena cava, compared with thoracic radiographs, but these findings do not correlate with histological diagnosis.[25] CT scans are also more sensitive for the diagnosis of pulmonary metastasis in dogs.[26] The benefits of CT scans are highlighted in the present series as none of the three dogs with carcinomas invasive into the cranial vena cava and/or heart or two dogs with metastasis to the lungs were diagnosed pre-operatively using standard three-view thoracic radiographs.

The majority of diagnostic tests used in this study were not specific for the definitive pre-operative diagnosis of cranial mediastinal carcinoma. This may not be clinically important because the recommended treatment for cranial mediastinal tumours other than lymphosarcoma is surgical resection. Hence, the most important aspect of these pre-operative tests is to differentiate lymphosarcoma from other cranial mediastinal tumours such as thymomas and carcinomas. Aspirates are recommended, but cytology can be inconclusive with only 7 of 17 mediastinal masses correctly diagnosed by cytology in one study.[21] In the present study, six of the eight tumours aspirated were correctly identified as either carcinomas or NE carcinomas. Flow cytometry was recently found to be a useful tool in differentiating cranial mediastinal lymphosarcomas, thymomas and carcinomas,[27] but this technique was not used in our study.

Radionuclide imaging has been described for diagnosing thyroid carcinomas in dogs (using either ^{99m}technetium pertechnetate or ^{131}iodine) and NE tumours in humans (using either radiolabelled metaiodobenzylguanidine and ^{111}indium-pentetreotide).[23,28,29] Nuclear scintigraphy with ^{131}iodine was used in two dogs in this series. One dog with a functional ectopic follicular cell thyroid carcinoma showed a positive scan and one dog with a nonthyroid NE carcinoma showed a negative scan. Thyroid tumours do not need to be functional for an abnormal scintigraphic study, although hyperthyroid dogs have a more intense uptake than euthyroid dogs.[23] Nuclear scintigraphy is particularly useful for identifying ectopic thyroid carcinomas and may also provide an indication of the likelihood of these tumours responding to either radioactive iodine treatment or external-beam radiation therapy.[6,10,22,30]

Surgical resection is the recommended treatment for dogs and humans with cranial mediastinal tumours other than lymphosarcoma.[12–14] The local invasive characteristic of both thyroid carcinomas and thymomas in dogs is an important factor in determining both surgical resectability and prognosis.[5,8,21] Three dogs in this study had tumour invasion into the cranial vena cava and/or heart, and this precluded resection in two of these dogs. One dog with invasion into the cranial vena cava and tumour thrombus formation had the tumour resected *en bloc* with a segment of the caval wall and tumour thrombus. This technique has been previously described in two dogs with invasive thymomas and highlights that invasive cranial mediastinal tumours are not necessarily unresectable.[31,32] The postoperative recovery in this series was typical for dogs following median sternotomy

for resection of cranial mediastinal tumours, although the incidence of PTE was higher than that expected.[21]

Radiation therapy is recommended as the primary treatment for dogs with invasive thyroid carcinomas and thymomas.[10,11,33,34] Radiation therapy has not been investigated in the treatment of humans with thymic NE carcinomas but has been recommended postoperatively because of high local recurrence rates.[12–14] External-beam radiation therapy was used in one dog in the present series but only to downstage the tumour pre-operatively to increase the likelihood of complete surgical resection. Radiation therapy results in prolonged MSTs in dogs with invasive thyroid carcinomas (more than 2 years)[10,11,33] and should be considered for dogs with unresectable cranial mediastinal thyroid carcinomas. However, only 8% of thyroid tumours have a complete response, and the median time to maximal response is between 6 and 22 months[10,11,33]; therefore, clinical signs may persist in irradiated dogs for a long period. The acute effects of irradiation of cranial mediastinal tumours include moist desquamation, pneumonitis and cardiotoxicity.[34,35]

Radioactive iodine therapy is an alternative treatment option to radiation therapy for dogs with unresectable cranial mediastinal thyroid carcinomas. The use of radioactive iodine has been described in dogs with both orthotopic and ectopic thyroid carcinoma.[36–38] Thyroid tumours do not need to be functional to respond to radioactive iodine therapy.[10,23,37,38] However, the clinical applicability is limited because radioactive iodine is not as effective for the treatment of large tumours, multiple doses are required to maintain therapeutic levels and prolonged hospitalization is necessary to comply with health and safety regulations.[10,22,36]

Adjunctive doxorubicin chemotherapy was administered in two dogs, one with anaplastic carcinoma and the other with follicular cell thyroid carcinoma. The role of chemotherapy in the treatment of dogs with thyroid tumours and humans with thymic NE carcinomas remains to be defined.[12] The use of either doxorubicin or cisplatin results in response rates of 30 to 50% in dogs with thyroid carcinomas, but decreased rates of metastasis and improved survival times have not been demonstrated.[39–41] Three dogs were diagnosed with metastatic disease at presentation in the present study, but no dogs developed metastasis after surgical treatment. Somatostatin analogues, such as octreotide, are recommended in humans with functional NE carcinomas because of good antiproliferative activity and ability to control clinical signs.[13,42,43] Interferon therapy is also recommended in the treatment of nonfunctional NE carcinomas in humans with durable response rates of up to 50%.[42]

The metastatic pattern for dogs with carcinomas of the cranial mediastinum was similar to that for dogs with thyroid carcinomas, with the lungs and regional lymph nodes most commonly affected.[3,6] One dog also had metastasis to the ribs and vertebrae, and this has also been reported in dogs with thyroid carcinoma.[30]

The overall MST, regardless of the type of carcinoma, was 243 days. The number of dogs diagnosed with ectopic thyroid, NE and anaplastic carcinomas was too small for meaningful statistical comparison. The majority of dogs died as a result of either postoperative complications or progression of local or metastatic disease. Surprisingly, the two dogs with incompletely resected mediastinal carcinomas had the longest survival times (512 and 607 days). Both of these dogs eventually died because of tumour progression, but these tumours were small at the time of surgery, measuring 3×4 to 6 cm and hence had sufficient space for growth prior to the development of debilitating clinical signs. Two of the three dogs with metastasis also had prolonged survival times (243 and 607 days), and there was no significant difference in survival times between dogs with and without metastasis. A similar finding has been reported in dogs with invasive thyroid carcinomas treated with hypofractionated radiation therapy.[33] Hence, the presence of metastasis at the time of diagnosis does not necessarily equate to a poorer prognosis in dogs with cranial mediastinal carcinomas. Although the sample population was small, local tumour invasion and pleural effusion also did not have a significant impact on survival time in the present series.

Conclusions

Carcinomas of the cranial mediastinum are rare in dogs but include ectopic thyroid, NE and

anaplastic carcinomas. These have a signalment and clinical presentation similar to those of thymomas and a biological behaviour similar to that of orthotopic thyroid carcinomas. Immunohistochemistry using a panel of thyroid-specific and NE-specific markers is necessary for definitive diagnosis. Surgical resection is recommended for definitive treatment, but radiation therapy may be indicated for unresectable tumours.

References

1. Day MJ. Review of thymic pathology in 30 cats and 36 dogs. *Journal of Small Animal Practice* 1997; **38**: 393–403.
2. Withrow SJ. Thymoma. In: *Small Animal Clinical Oncology*, 3rd edn., SJ Withrow and EG MacEwen, eds., Philadelphia, Saunders, 2001: 646–651.
3. Capen CC. Tumors of the endocrine glands. In: *Tumors in Domestic Animals*, 4th edn., DJ Meuten, ed., Ames, Iowa State Press, 2002: 607–696.
4. Kameda Y. Accessory thyroid glands of the dog around the intrapericardial aorta. *Archivum Histologicum Japonicum* 1972; **34**: 375–391.
5. Carver JR, Kapatkin A and Patnaik AK. A comparison of medullary thyroid and thyroid adenocarcinoma in dogs: a retrospective study of 38 cases. *Veterinary Surgery* 1995; **24**: 315–319.
6. Page RL. Tumors of the endocrine system. In: *Small Animal Clinical Oncology*, 3rd edn., SJ Withrow and EG MacEwen, eds., Philadelphia, Saunders, 2001: 423–427.
7. Patnaik AK and Lieberman PH. Gross, histologic, cytochemical, and immunocytochemical study of medullary thyroid carcinoma in sixteen dogs. *Veterinary Pathology* 1991; **28**: 223–233.
8. Klein MK, Powers BE, Sithrow SJ, Curtis CR, Straw RC, Ogilvie GK, Dickinson KL, Cooper MF and Baier M. Treatment of thyroid carcinoma in dogs by surgical resection alone: 20 cases (1981–1989). *Journal of the American Veterinary Medical Association* 1995; **206**: 1007–1009.
9. Leav I, Schiller AL, Rijnberk A, Legg MA and der Kinderen MJ. Adenomas and carcinomas of the canine and feline thyroid. *American Journal of Pathology* 1976; **83**: 61–122.
10. Théon AP, Marks SL, Feldman ES and Griffey S. Prognostic factors and patterns of treatment failure in dogs with unresectable differentiated thyroid carcinomas treat ed with megavoltage irradiation. *Journal of the American Veterinary Medical Association* 2000; **216**: 1775–1779.
11. Pack LA, Roberts RE, Dawson SD and Dookwah HD. Definitive radiation therapy for infiltrative thyroid carcinoma in dogs. *Veterinary Radiology and Ultrasound* 2001; **42**: 471–474.
12. Aisner J, Belani CP and Aisner SC. Tumors of the pleura and mediastinum. In: *Clinical Oncology*, 3rd edn., MD Abeloff, JO Armitage, JE Niederhuber, MB Kastan and WG McKenna, eds., Philadelphia, Elsevier Churchill Livingstone, 2004: 1745–1786.
13. Filosso PL, Dato GMA, Ruffini E, Bretti S, Ozzello F and Mancuso M. Multidisciplinary treatment of advanced thymic neuroendocrine carcinoma (carcinoid): report of a successful case and review of the literature. *Journal of Thoracic and Cardiovascular Surgery* 2004; **127**: 1215–1219.
14. Cameron RB, Loehrer PJ and Thomas CR. Neoplasms of the mediastinum. In: *Cancer: Principles and Practice of Oncology*, 7th edn., VT DeVita, S Hellman and SA Rosenberg, eds., Philadelphia, Lippincott Williams & Wilkins, 2005: 845–860.
15. Patnaik AK, Newman SJ, Scase T, Erlandson RA, Antonescu C, Craft D and Bergman PJ. Canine hepatic neuroendocrine carcinoma: an immunohistochemical and electron microscopic study. *Veterinary Pathology* 2005; **42**: 140–146.
16. Moore FM, Kledzik GS, Wolfe HJ and DeLellis RA. Thyroglobulin and calcitonin immunoreactivity in canine thyroid carcinomas. *Veterinary Pathology* 1984; **21**: 168–173.
17. Ramos-Vera JA, Miller MA, Johnson GC and Pace LW. Immunohistochemical detection of thyroid transcription factor-1, thyroglobulin, and calcitonin in canine normal, hyperplastic, and neoplastic thyroid gland. *Veterinary Pathology* 2002; **39**: 480–487.
18. Hullinger RL. The endocrine system. In: *Miller's Anatomy of the Dog*, 2nd edn., HE Evans and GC Christensen, eds., Philadelphia, Saunders, 1979: 602–631.
19. Holscher MA, Davis BW, Wilson RB, Hunt KL and Berry KK. Ectopic thyroid carcinoma in a dog: thyroglobulin, calcitonin, and neuron-specific enolase immunocytochemical studies. *Veterinary Pathology* 1986; **23**: 778–789.
20. Goto K, Kodama T, Matsuno Y, Yokose T, Asamura H, Kamiya N and Shimosato Y. Clinicopathologic and DNA cytometric analysis of carcinoid tumors of the thymus. *Modern Pathology* 2001; **14**: 985–994.
21. Atwater SW, Powers BE, Park RD, Straw RC, Ogilvie GK and Withrow SJ. Thymoma in dogs: 23 cases (1980–1991). *Journal of the American Veterinary Medical Association* 1994; **205**: 1007–1013.

22. Peterson ME, Kintzer PP, Hurley JR and Becker DV. Radioactive iodine treatment of a functional thyroid carcinoma producing hyperthyroidism in a dog. *Journal of Veterinary Internal Medicine* 1989; **3**: 20–25.
23. Marks S, Koblik P, Hornof W and Feldman EC. 99mTc-pertechnetate imaging of thyroid tumors in dogs: 29 cases (1980–1992). *Journal of the American Veterinary Medical Association* 1994; **204**: 756–760.
24. Kent MS, Griffey SM, Verstraete FJM, Naydan D and Madewell BR. Computer-assisted image analysis of neovascularization in thyroid neoplasms from dogs. *American Journal of Veterinary Research* 2002; **63**: 363–369.
25. Yoon J, Feeney DA, Cronk DE, Anderson KL and Ziegler LE. Computed tomographic evaluation of canine and feline mediastinal masses in 14 patients. *Veterinary Radiology and Ultrasound* 2004; **45**: 542–546.
26. Nemanic S, London CA and Wisner ER. Comparison of thoracic radiographs and single breath-hold helical CT for detection of pulmonary nodules in dogs with metastatic neoplasia. *Journal of Veterinary Internal Medicine* 2006; **20**: 508–515.
27. Lana S, Plaza S, Hampe K, Burnett R and Avery AC. Diagnosis of mediastinal masses in dogs by flow cytometry. *Journal of Veterinary Internal Medicine* 2006; **20**: 1161–1165.
28. Harari J, Patternson JS and Rosenthal RC. Clinical and pathologic features of thyroid tumors in 26 dogs. *Journal of the American Veterinary Medical Association* 1986; **188**: 1160–1164.
29. Bombardieri E, Maccauro M, de Deckere E, Savelli G and Chiti A. Nuclear medicine imaging of neuroendocrine tumours. *Annals of Oncology* 2001; **12**(Suppl. 2): S51–S61.
30. Mooney CT. Hyperthyroidism. In: *Textbook of Veterinary Internal Medicine: Diseases of the Dog and Cat*, 6th edn., SJ Ettinger and EC Feldman, eds., St. Louis, Elsevier Saunders, 2005: 1544–1560.
31. Hunt GB, Churcher RK, Church DB and Mahoney P. Excision of a locally invasive thymoma causing cranial vena cava syndrome in a dog. *Journal of the American Veterinary Medical Association* 1997; **210**: 1628–1630.
32. Holsworth IG, Kyles AE, Bailiff NL, Hopper K, Long C and Ilkiw JE. Use of a jugular vein autograft for reconstruction of the cranial vena cava in a dog with invasive thymoma and cranial vena cava syndrome. *Journal of the American Animal Hospital Association* 2004; **225**: 1205–1210.
33. Brearley MJ, Hayes AM and Murphy S. Hypofractionated radiation therapy for invasive thyroid carcinoma in dogs: a retrospective analysis of survival. *Journal of Small Animal Practice* 1999; **40**: 206–210.
34. Smith AN, Wright JC, Brawner WR, LaRue SM, Fineman L, Hogge GS, Kitchell BE, Hohenhaus AE, Burk RL, Dhaliwal RS and Duda LE. Radiation therapy in the treatment of canine and feline thymomas: a retrospective study (1985–1999). *Journal of the American Animal Hospital Association* 2001; **37**: 489–496.
35. Mantini G, Smaniotto D, Balducci M, Dinapoli N, Campitelli M, Corvari B, Simili A and Ciarniello V. Radiation-induced cardiovascular disease: impact of dose and volume. *Rays* 2005; **30**: 157–168.
36. Adams WH, Walker MA, Daniel GB, Petersen MG and Legendre AM. Treatment of differentiated thyroid carcinoma in 7 dogs utilizing ^{131}I. *Veterinary Radiology and Ultrasound* 1995; **36**: 417–424.
37. Worth AJ, Zuber RM and Hocking M. Radioiodide (^{131}I) therapy for the treatment of canine thyroid carcinoma. *Australian Veterinary Journal* 2005; **83**: 208–214.
38. Turrel JM, McEntee MC, Burke BP and Page RL. Sodium iodide I 131 treatment of dogs with nonresectable thyroid tumors: 39 cases (1990–2003). *Journal of the American Veterinary Medical Association* 2006; **229**: 542–548.
39. Jeglum KA and Whereat A. Chemotherapy of canine thyroid carcinoma. *Compendium on the Continuing Education for the Practicing Veterinarian* 1983; **5**: 96–98.
40. Post GS and Mauldin GN. Radiation and adjuvant chemotherapy for the treatment of thyroid adenocarcinoma in dogs [Abstract]. *Veterinary Cancer Society Conference* 1992; **12**: 43–44.
41. Fineman LS, Hamilton TA, de Gortari A and Booney P. Cisplatin chemotherapy for treatment of thyroid carcinoma in dogs: 13 cases. *Journal of the American Animal Hospital Association* 1998; **34**: 109–112.
42. Öberg K. Chemotherapy and biotherapy in the treatment of neuroendocrine tumours. *Annals of Oncology* 2001; **12**(Suppl. 2): S111–S114.
43. Dogliotti L, Tampellini M, Stivanello M, Gorzegno G and Fabiani L. The clinical management of neuroendocrine tumors with long-acting repeatable (LAR) octreotide: comparison with standard subcutaneous octreotide therapy. *Annals of Oncology* 2001; **12**(Suppl. 2): S105–S109.