Prostatic Abscess in a Neutered Cat

A 6-year-old, male castrated domestic shorthair cat was presented for evaluation of lethargy, vomiting, anorexia, and constipation. Physical examination revealed an elevated body temperature and an extramural colonic mass. Abdominal ultrasonography demonstrated a hypoechoic mass measuring 2.2 cm in maximum dimension immediately caudal to the bladder. Cytological evaluation of a fine-needle aspirate confirmed the mass was a prostatic abscess. Abdominal celiotomy and prostatic omentalization were successful in resolving clinical abnormalities. Feline prostatic abscessation is a rare condition that has not been previously reported and may have a good outcome if treated early and appropriately. **J Am Anim Hosp Assoc 2008;44:90-94.**

Adam Mordecai, DVM, Diplomate ACVIM

Julius M. Liptak, BVSc, MVetClinStud, Fellow ACVSc, Diplomate ACVS, Diplomate ECVS

Tamara Hofstede, DVM

Margaret Stalker, BSc, DVM, PhD, Diplomate ACVP

Stephen Kruth, DVM, Diplomate ACVIM

C

From the Department of Veterinary Clinical Sciences (Mordecai), College of Veterinary Medicine, Washington State University, P.O. Box 646610, Pullman, Washington 99164-6610; the Departments of Clinical Studies (Liptak, Kruth) and Pathobiology (Stalker), Ontario Veterinary College, University of Guelph, Guelph, Ontario, Canada N1G 2W1; Woodstock Veterinary Hospital (Hofstede), 866 Nellis, Woodstock, Ontario, Canada N4S 4C4.

Introduction

Prostatic disease is exceedingly rare in the cat. Previous reports of feline prostatic disease have described bacterial prostatitis in an intact cat,[3] a paraprostatic cyst,[4] and prostatic neoplasia.[5-8] Canine prostatic disease is also uncommon and represents approximately 2.5% of the total number of male dogs examined.[1] Bacterial prostatitis is the most common prostatic disease diagnosed in dogs, while prostatic abscesses are relatively uncommon—representing only 2.3% of prostatic diseases in one retrospective study.[1] Neutered males are less commonly affected with prostatitis compared to intact dogs, but they still represented 13% of dogs in another study.[2] The purpose of this report is to describe the presentation, diagnostic plan, and treatment of prostatic abscess in a neutered cat.

Case Report

A 6-year-old, 5.2-kg, castrated male American domestic shorthair was referred to the Ontario Veterinary College (OVC) with an acute onset of straining to defecate, lethargy, vomiting, and anorexia. The owner reported the cat failed to defecate despite straining for 24 hours. Examination at an emergency center 1 day prior to referral revealed a colon enlarged with feces. Results of a complete blood count were within the normal reference range. A serum biochemical profile identified no abnormalities with the exception of hyperglycemia (180.7 mg/dL, reference range 75.6 to 145.2 mg/dL). On abdominal radiographs, the colon was distended with feces, and an extramural mass (suspected to be the prostate) was present in the caudal abdomen. A soft, symmetrical, nonpainful mass in the region of the prostate was palpated during digital rectal examination. The constipation and resulting colonic distention were assumed to result from partial extramural colonic obstruction by the enlarged prostate. Initial treatment consisted of intravenous fluid therapy, oral lactulose, forced feedings, and frequent enemas.

On the cat's presentation to the OVC, temperature and pulse were 103.8˚F and 140 beats per minute, respectively. Mucous membranes were pink and moist, and hydration status was adequate. Rectal palpation revealed an approximately 3 cm-diameter extramural mass about 3 cm orad to the anus. The mass was smooth, symmetrical, bilobed, and nonpainful, and it could not be palpated transabdominally. The colon was

impacted with stool. Differential diagnoses for prostatomegaly included prostatic neoplasia, prostatic abscess, prostatic cyst, paraprostatic cyst, and bacterial prostatitis.

Abdominal ultrasonography demonstrated a hypoechoic mass, with anechoic foci, measuring 2.2 cm in maximum dimension immediately caudal to the urinary bladder [Figure 1]. Both kidneys had abnormally echogenic cortices, and the right renal pelvis and proximal 2 cm of the ureter were dilated. No obstructive lesion was identified.

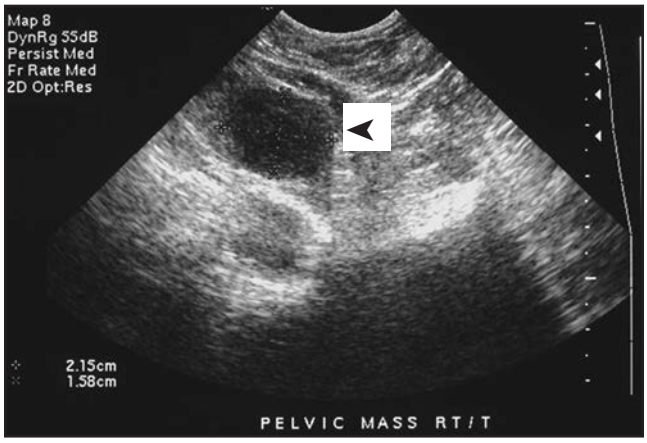

Figure 1—Transverse ultrasonographic image of the right lobe of the prostate. Note the 2.0 × 1.5-cm hypoechoic abscess within the parenchyma of the prostate (arrow).

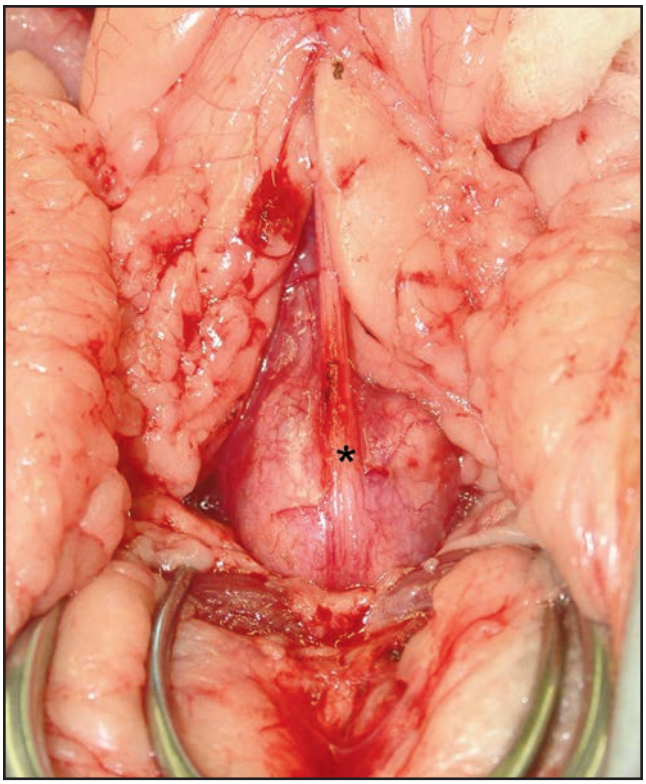

Figure 2—Intraoperative photograph of the smooth, bilobed, enlarged prostate prior to omentalization. The asterisk (*) indicates the urethra.

Cystocentesis, fine-needle aspiration of the mass, and colonic evacuation were performed. Prostatic aspirates appeared grossly purulent, and colonic and rectal evacuation removed the remaining fecal material. Results of urinalysis included a specific gravity of 1.006, pH of 7.0, 2000 mg/dL proteinuria, 15 to 20 leukocytes and 15 to 20 red blood cells per high-power field, occasional epithelial transitional cells, and bacteruria. The cellularity of prostate smears was high and predominated by degenerate neutrophils. Macrophages were also observed, but they were rare. Large numbers of pleomorphic bacteria (cocci and rods) were seen intracellularly and extracellularly. Based on these findings, a diagnosis of prostatic abscess was made. However, concurrent prostatic neoplasia could not be excluded.

A midline celiotomy was performed, and visual inspection confirmed the palpable mass was the prostate [Figure 2]. In addition, the left adrenal gland was mildly enlarged. Impression smears of fine-needle aspirates of the adrenal gland were submitted for cytological evaluation. The prostate was isolated with moistened laparotomy sponges and incised on the ventrolateral aspect of both the left and right prostatic lobes. Thick, hemorrhagic, purulent prostatic contents were removed by suction. Prostatic biopsies were collected and submitted for bacterial culture and sensitivity and histopathological examination. A single prostatic cavity and resultant communication between the left and right lateral incisions were created by breaking down the abscessed prostatic parenchyma with a Poole suction tip. The prostatic abscess was omentalized by passing omentum sequentially through the right lateral incision, through the prostatic cavity ventral to the prostatic urethra, and through the left lateral incision; then it was sutured back onto itself [Figure 3].[9] Following completion of prostatic omentalization, the abdomen was thoroughly lavaged. An esophageal feeding tube was placed because of preoperative anorexia. The cat recovered without complication in the intensive care unit. Postoperative analgesia included fentanyl (3 μg/kg per hour) intravenously (IV) and a single loading dose of meloxicam (0.2 mg/kg IV). Feedings were initiated through the esophageal tube the following day. Antibiotic therapy consisted of amoxicillin-clavulanic acid[a] (62.5 mg orally *q* 8 hours), and lactulose was continued (1 mL orally *q* 8 hours).

Prostatic histopathological evaluation confirmed the presence of chronic, suppurative, granulomatous prostatitis. Normal prostatic architecture was disrupted by marked inflammation [Figure 4], and no evidence of malignancy was seen. Special stains (Ziehl-Neelsen and Fites' modified acid fast, Brown and Brenn tissue gram stain, periodic acid Schiff, and Gomori's methenamine silver) were all negative for organisms. Adrenal impression smears were nondiagnostic.

Escherichia coli (*E. coli*), susceptible to a wide variety of antimicrobials including amoxicillin-clavulanic acid, was isolated from cultures of urine and prostatic exudate.

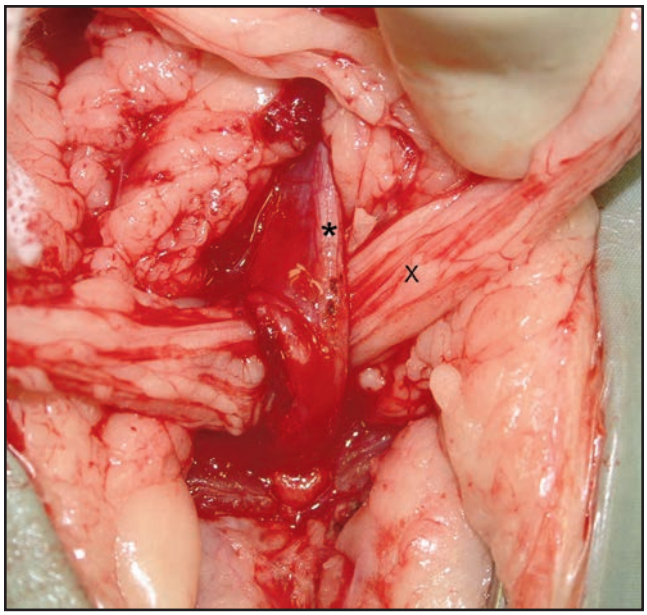

Figure 3—Intraoperative photograph of the prostate after prostatic debridement, suction of purulent material, and omentalization. The asterisk (*) indicates the urethra; **X** indicates omentum.

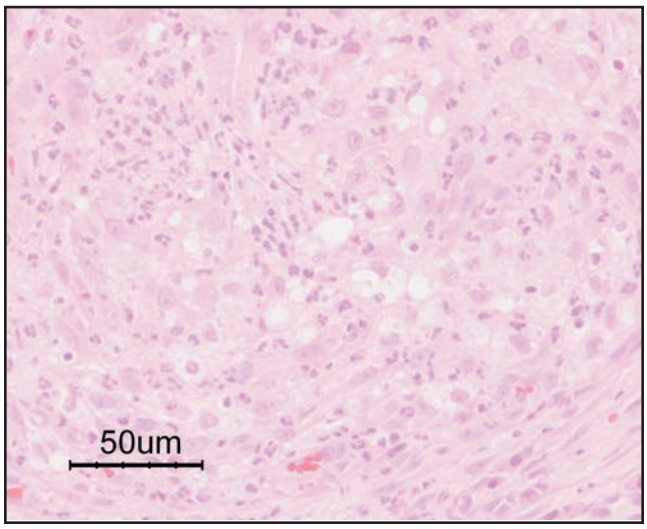

Figure 4—Normal prostatic architecture is obscured by marked pyogranulomatous inflammation, with a peripheral infiltrate of lymphocytes and plasma cells.

Antibiotic selection was not altered. The cat was discharged 2 days after surgery.

Follow-up evaluation was performed by the referring veterinarian. The cat remained constipated for 6 weeks and required periodic enemas and continued use of stool softeners, despite a marked reduction in prostatic size. Treatment with cisapride for management of the constipation was recommended but declined by the owner. Anorexia resolved after 2 weeks, prompting removal of the esophageal feeding tube. Anorexia returned shortly thereafter and continued until resolution of the constipation. Treatment of the anorexia continued with forced feedings until the appetite returned to normal. The cat made a full recovery and has remained free of symptoms for 3 years.

Discussion

Prostatic abscessation is considered the consequence of chronic and severe bacterial prostatitis. Proposed mechanisms of prostatitis include contamination from prostatic cyst,[10] ascending bacterial infection, and hematogenous spread.[11] Predisposing factors for prostatic infection include urethral disease interfering with normal host defense mechanisms (e.g., urolithiasis and neoplasia); diseases that alter normal prostatic architecture and interfere with formation and secretion of prostatic fluid (e.g., cyst, neoplasia, and benign prostatic hyperplasia); and drugs (e.g., estrogen).[12] Predisposing anatomical or architectural abnormalities were not identified in this cat; however, hormonal alterations may have existed given the subjective adrenal gland enlargement. Adrenal biopsy and histopathology would have presented more information than adrenal impression smears. Increased serum estrogen-to-androgen ratio has been proposed to predispose to benign prostatic hyperplasia (BPH) by altering sensitivity of the prostate to these hormones.[13] Ectopic or remnant testicular tissue may lead to these hormonal alterations in a neutered male. Identification of androgen-dependent penile spines, remnant tissue during laparotomy, or elevated serum testosterone concentration following injection of human chorionic gonadotropin or gonadotropin-releasing hormone supports a diagnosis of cryptorchidism.[14] No reports of concurrent adrenal-induced prostatic disease have been reported in veterinary patients; however, one case report of a human hermaphrodite and concurrent BPH indicates this can occur.[15]

The observed gastrointestinal signs (i.e., anorexia, vomiting, and constipation) in this cat were similar to those described in a previous report of feline bacterial prostatitis.[3] Pyrexia was attributed to prostatic abscessation, and it is a known feature of the disease in dogs.[11] Other contributing factors to pyrexia may include stress, constipation and secondary gastrointestinal bacterial translocation, or pyelonephritis secondary to an ascending bacterial infection.[18] Other commonly reported clinical signs of prostatitis in dogs include dysuria, stranguria, and hematuria.[1,11,17,19] The anatomy and location of the feline prostate differ from the prostate in dogs. The prostate in cats lies further caudally at the cranial brim of the pelvis, midway between the root of the penis and neck of the bladder. It is bilobed with the urethra only covered by the prostate dorsally and laterally.[7] Given the location of the prostate and resolution of clinical signs following appropriate surgical and medical management, constipation was most likely caused by prostatic enlargement resulting in extramural compression of the colon.

The prostatic abscess was diagnosed in this cat based on ultrasound and intraoperative findings, prostatic cytology and histopathology, and culture and sensitivity results. Abdominal ultrasonography is the most reliable noninvasive tool for differentiating bacterial prostatitis from pros-

tatic abscess.[23] Focal to multifocal areas of increased echogenicity are seen in dogs with bacterial prostatitis or neoplasia. Fluid-filled hypoechoic to anechoic cavities are seen in dogs with parenchymal abscesses or paraprostatic cysts.[4,23] The ultrasonographic appearance of the prostate in the present case was consistent with previous reports of prostatic abscessation in dogs. Histopathology and culture and sensitivity results are required for definitive diagnosis of prostatic abscess and exclusion of concurrent prostatic neoplasia.[23,24] In this cat, urine and prostatic fluid both yielded *E. coli*, and histopathology was consistent with prostatic abscessation without concomitant neoplasia.

Escherichia coli is the most common isolate in dogs with prostatic abscesses, followed by *Staphylococcus aureus*, *Klebsiella* spp., *Proteus mirabilis*, *Mycoplasma canis*, *Pseudomonas aeruginosa*, *Enterobacter* spp., *Streptococcus* spp., *Pasteurella* spp., and *Haemophilus* spp.[1,11,16] Bacterial infection results in parenchymal microabscesses that ultimately coalesce into larger, loculated abscesses.[9] Abscesses can rupture into the retroperitoneum or peritoneum, causing peritonitis.[17]

The blood-prostate barrier is considered intact with abscessation of the prostate, which explains the relative difficulty in successfully treating prostatic abscesses with antimicrobials.[25] Factors affecting antimicrobial penetration of the prostate include pH, lipid solubility, and protein binding in plasma. Lipophilic, basic antimicrobials with low protein binding in plasma have good penetration and ion trapping. Antimicrobials with these characteristics include chloramphenicol, erythromycin, clindamycin, trimethoprim, doxycycline, ciprofloxacin, enrofloxacin, and carbenicillin.[28] Clindamycin or erythromycin is an appropriate first-line antimicrobial due to the common prevalence of *E. coli* infections.[25] Empirical therapy should be altered if culture and sensitivity results indicate poor sensitivity. Amoxicillin-clavulanic acid does not possess prostatic penetrating properties; however, the authors suspected surgical treatment compromised the blood-prostate barrier, thereby minimizing the need for lipophilic antimicrobials. To the authors' knowledge, no studies have evaluated the effect of antimicrobial penetration following prostatic drainage and omentalization.

Although bacterial prostatitis may be effectively treated with antimicrobial therapy, prostatic abscesses usually require surgical intervention such as debridement and omentalization, subtotal prostatectomy, Penrose drain placement, or marsupialization.[9,10,25,26] Omentalization is currently the recommended technique for management of prostatic abscesses in dogs, because success rates are good and postoperative complications are minimal.[9,27] Although ultrasound-guided percutaneous drainage is described to treat prostatic abscesses,[19] abdominal celiotomy was selected for this cat in order to resolve the colonic obstruction and obtain a biopsy to exclude neoplasia as an inciting cause. Surgical drainage techniques can be associated with a high perioperative rate of complications that include urinary incontinence, scrotal and pelvic limb edema, peritonitis, recurrence, sepsis, shock, and death.[9,10,19,26]

Conclusion

A rare diagnosis of prostatic abscess was made in a neutered cat. When prostatic enlargement is identified in cats, an aggressive diagnostic approach should be pursued. Despite the rarity of feline bacterial prostatitis and abscessation, these diseases should be considered as differentials for prostatomegaly. Underlying processes such as primary or secondary prostatic neoplasia, immunosuppression, or hormonal alterations from estrogen drugs should be ruled out. Based on this single case report, a good result is possible if the cat is treated early and appropriately.

Footnotes

[a] Clavamox; Pfizer Animal Health, Exton, PA 19341

References

1. Krawiec DR, Heflin D. Study of prostatic disease in dogs: 177 cases (1981-1986). J Am Vet Med Assoc 1992;200:1119-1122.
2. Mullen HS, Mathiesen DT, Scavelli TD. Results of surgery and postoperative complications in 92 dogs treated for prostatic abscessation by a multiple Penrose drain technique. J Am Anim Hosp Assoc 1990;26:369-379.
3. Roura X, Camps-Palau MA, Lloret A, Garcia F, Espada I. Bacterial prostatitis in a cat. J Vet Intern Med 2002;16:593-597.
4. Newell SM, Mahaffey MB, Binhazim A, Greene CE. Paraprostatic cyst in a cat. J Small Anim Pract 1992;33:399-401.
5. Hawe RS. What is your diagnosis? Prostatic adenocarcinoma. J Am Vet Med Assoc 1983;182:1257-1258.
6. Hubbard BS, Vulgamott JC, Liska WD. Prostatic adenocarcinoma in a cat. J Am Vet Med Assoc 1990;197:1493-1494.
7. Caney SM, Holt PE, Day MJ, Rudorf H, Gruffydd-Jones TJ. Prostatic carcinoma in two cats. J Small Anim Pract 1998;39: 140-143.
8. LeRoy BE, Lech ME. Prostatic carcinoma causing urethral obstruction and obstipation in a cat. J Feline Med Surg 2004;6:397-400.
9. White RA, Williams JM. Intracapsular prostatic omentalization: a new technique for management of prostatic abscesses in dogs. Vet Surg 1995;24:390-395.
10. Basinger RR, Robinette CL, Spaulding KA. Prostate. In: Slatter D, ed. Textbook of Small Animal Surgery. 3rd ed. Saunders, 2003: 1542-1557.
11. Kutzler MA, Yeag A. Prostatic diseases. In: Textbook of Veterinary Internal Medicine. 6th ed. Elsevier Inc, 2005:1809-1824.
12. Barsanti J, Finco DR. Medical management of canine prostatic hyperplasia. In: Bonagura JD, ed. Kirk's Current Veterinary Therapy. 12th ed. Saunders, 1995:1033-1034.
13. Brendler CB, Berry SJ, Ewing LL, *et al.* Spontaneous benign prostatic hyperplasia in the beagle. Age-associated changes in serum hormone levels, and the morphology and secretory function of the canine prostate. J Clin Invest 1983;71:1114-1123.
14. Johnston SD, Kustritz MV, Olson PNS. Disorders of the feline testes and epididymides. In: Kersey R, ed. Canine and Feline Theriogenology. Saunders, 2001:525-536.
15. Heyns CF, Rimington PD, Kurger TF, Falck VG. Benign prostatic hyperplasia and uterine leiomyomas in a female pseudohermaphrodite: a case report. J Urol 1987;137:1245-1247.
16. Barsanti JA, Finco DR. Canine prostatic diseases. Vet Clin North Am Small Anim Pract 1986;16:587-599.
17. Bauer MS. Prostatic abscess rupture in three dogs. J Am Vet Med Assoc 1986;188:735-737.
18. Allen TA. Pyelonephritis in the dog. The Compendium on Continuing Education 1985;7:421-428.
19. Boland LE, Hardie RJ, Gregory SP, Lamb CR. Ultrasound-guided percutaneous drainage as the primary treatment for prostatic abscesses and cysts in dogs. J Am Anim Hosp Assoc 2003;39:151-159.

20. Barsanti JA, Finco DR. Evaluation of techniques for diagnosis of canine prostatic diseases. J Am Vet Med Assoc 1984;185:198-200.
21. Barsanti JA, Prasse KW, Crowell WA, Shotts EB, Finco DR. Evaluation of various techniques for diagnosis of chronic bacterial prostatitis in the dog. J Am Vet Med Assoc 1983;183:219-224.
22. Ling GV, Branam JE, Ruby AL, Johnson DL. Canine prostatic fluid: techniques of collection, quantitative bacterial culture, and interpretation of results. J Am Vet Med Assoc 1983;183:201-206.
23. Feeney DA, Johnston GR, Klausner JS, Perman V, Leininger JR, Tomlinson MJ. Canine prostatic disease—comparison of ultrasonographic appearance with morphologic and microbiologic findings: 30 cases (1981-1985). J Am Vet Med Assoc 1987;190:1027-1034.
24. Rohleder JJ, Jones JC. Emphysematous prostatitis and carcinoma in a dog. J Am Anim Hosp Assoc 2002;38:478-481.
25. Dorfman M, Barsanti J. CVT update: treatment of canine bacterial prostatitis. In: Bonagura JD, ed. Kirk's Current Veterinary Therapy. 12th ed. Saunders, 1995:1029-1032.
26. Gourley LG. Marsupialization—a treatment for prostatic abscess in the dog. J Am Anim Hosp Assoc 1966;2:100-105.
27. Basinger RR, Robinette CL, Spaulding KA. Prostate. In: Slatter D, ed. Textbook of Small Animal Surgery. 3rd ed. Saunders, 2003: 1542-1557.
28. Dorfman M, Barsanti J, Budsberg SC. Enrofloxacin concentrations in dogs with normal prostate and dogs with chronic bacterial prostatitis. Am J Vet Res 1995;56:386-390.
29. Cowan LA, Barsanti JA, Crowell W, Brown J. Effects of castration on chronic bacterial prostatitis in dogs. J Am Vet Med Assoc 1991;199:346-350.